

AN ANATOMICAL STUDY ON THE LOWER EXTENSION OF THE DORSAL VAGAL NUCLEUS TO THE UPPER CERVICAL CORD IN THE SPERM WHALE

YASUSHI SEKI

Department of Anatomy, Nihon University School of Medicine, Tokyo

ABSTRACT

The lower portion of the dorsal vagal nucleus was examined anatomically in two specimens of sperm whale. At the level below the obex, the nucleus seems to be divided into two cell groups, medial and lateral. The medial cell groups of both sides are fused with each other on the midline, which is characteristic in the sperm whale. The lateral cell group makes islands-like cell column along the long axis of the central nervous system. In some sections, these two cell groups are observed to be in complete continuity. Caudalwards, they can be traced up to the first cervical level, decreasing number of cells and presenting beaded appearance. Thus, I could reconfirm that the lower extension of the dorsal vagal nucleus of the sperm whale belongs to the type 3 in my previous classification.

INTRODUCTION

Although the lowest portion of the dorsal vagal nucleus is difficult to give a definite description as to where to end and how, it usually is located approximately at the level of the pyramidal decussation. In certain other mammals the nucleus is reported to be further extended to the lower direction. But not much attention has been paid on this latter fact.

Ogawa and Chen (1947) found that the lowest part of this nucleus was directly continued to the lateral horn nucleus of the upper cervical cord in the goat and deer, and similar finding was obtained in the sea lion by Mannen and Seki (1958). Seki (1966) had classified the form of the lowest portion of the dorsal vagal nucleus in four types after comparative anatomical examination of such structures in many species of mammals including primates, carnivores, ungulates, rodents and cetaceas.

In this report, it was able to reconfirm that the lower extension of the nucleus belongs to the third type of the preceding classification, by a detailed observation in two cases of the sperm whale.

MATERIALS AND METHODS

The materials were parts of those which had been collected by Dr. T. Kojima*,

* Professor, Dept. of Anatomy, Nihon Univ. School of Med.

when he was on a whaling expedition in the Antarctic Ocean in 1949–50. Many thanks are due to the profound kindness of Dr. Kojima to offer me the precious materials to the present work.

The first specimen was the portion, 28 mm in length, covering from the level 3.7 mm above the obex to the upper end of the spinal cord including the first cervical cord. The second was the part, 44 mm in length, extending from the level 10 mm above the obex to that part which included the first cervical cord. These two had been preserved in formalin. Both materials, after having been cut off to meet the purpose, they were refixed in Müller's solution in 37°C for two weeks and mounted in celloidin through the usual manner. Serial sections of 35 μ in thickness, along the transverse plane for the first case and horizontal plane for the second, were made. Each fifth sections (the first and sixth and so forth with the last order of each figure being 1 and 6) were stained by the Klüver-Barrera method and each 10th sections (10th, 20th, 30th, etc.) were also treated by the Weigert-Pal or Kultschitzky's method for myelin staining.

RESULTS

The dorsal vagal nucleus and its lower extension are seen as palely stained areas in the myelin stained sections and they are easily discriminated as a prominent cell group distinctly bordered from the surrounding (Pl. I, Fig. 1). The examination of the cell staining preparates reveals that substantially large cells, ellipsoidal or spindle-shaped, constitute the principal cellular component of the nucleus (Pl. I, Fig. 2). In transverse sections, majority of cells possesses long axis in the direction oriented from the dorsomedial to ventrolateral, with approximately 50–100 μ in the long diameter and 30–60 μ in the short one. They are large in size next to cells of the hypoglossal nucleus in the lower medulla or the anterior horn of the upper spinal cord of the sperm whale.

On the lateral or the dorsolateral to the nucleus is another aggregation of small cells, part of which is found in a small number, though, within the above mentioned large cell group.

Fig. 1. Approximate distribution of cells in transverse sections of the lower medulla and the 1st cervical cord in case 1, Klüver-Barrera, $\times 12$.

Each of drawings was made by accumulation of neighbouring 4 sections (stained every 5th sections) on one plane. Cells of dorsal vagal nucleus and its lower extension were indicated by black dots.

- a: Lower medulla above the obex (Section numbers; 281, 286, 291 and 296 of block 2.). Note the hypoglossal nucleus lying far ventral apart from the bottom of the 4th ventricle.
- b: Lowest medulla (Section numbers; 421, 426, 431 and 436 of block 1.). Dorsal vagal nucleus is extended laterally and makes lateral cell group of lower extension.
- c: First cervical cord (Section numbers; 101, 106, 111 and 116 of block 1.). Medial cell groups of lower extension of both sides are completely fused on the midline.

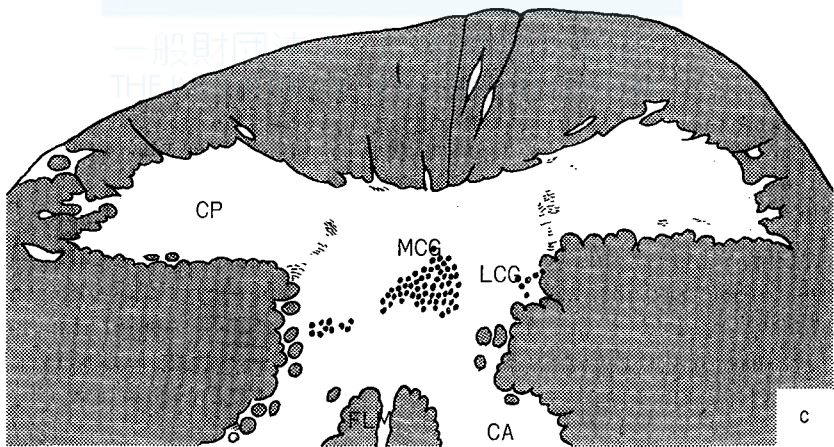
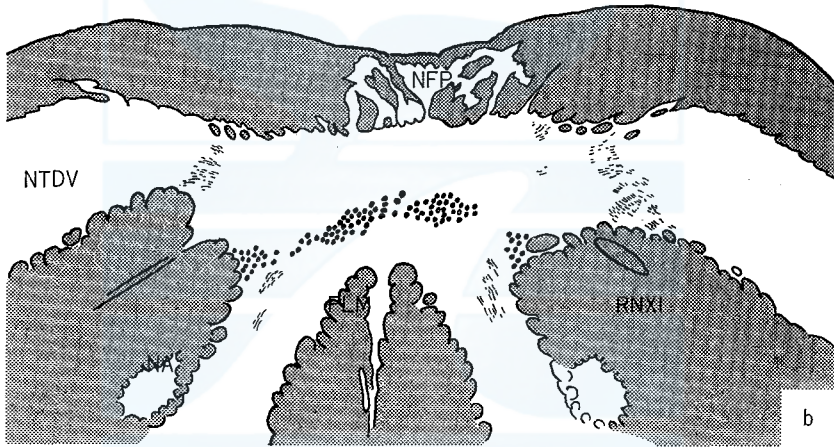
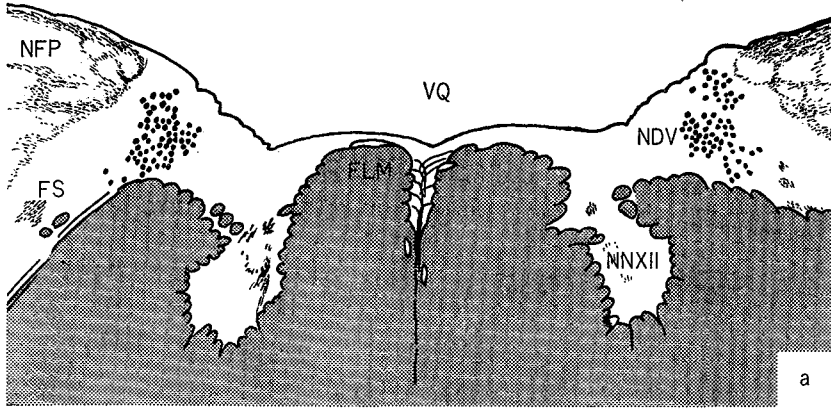


Fig. 1.

Other than these two different cell groups, there exist small collections of cells, apparently similar in nature to those in the dorsal vagal nucleus, located in the reticular formation of the lower medulla and the lateral funiculus of the upper cervical cord, distributed longitudinally with islands-like interruptions. But owing to the limitation of the material obtained, no relationship of these cell groups with the dorsal vagal nucleus or its lower extension could be clarified in this study.

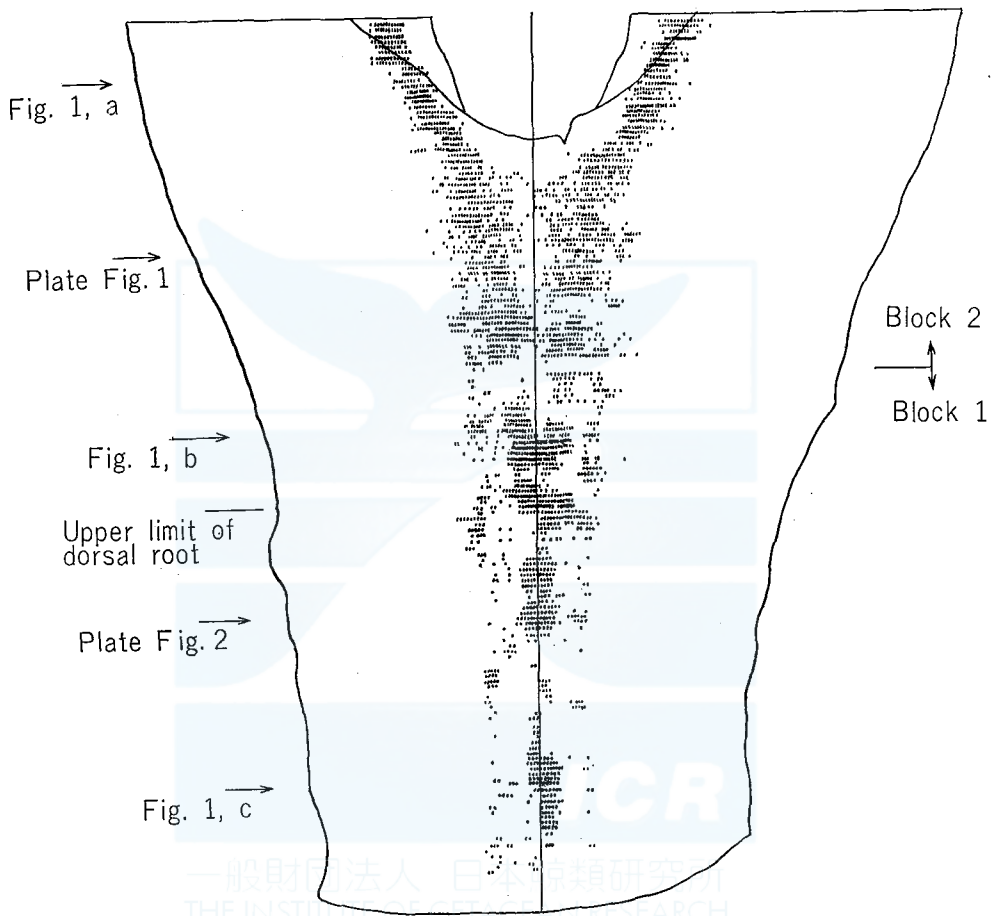


Fig. 2. Approximate distribution of cells projected from transverse sections (stained every 5th sections) on the horizontal plane in case 1, Klüber-Barrera, $\times 4.5$. Arrows in left show levels of figures 1 and plate.

In the level higher than the obex, the dorsal vagal nucleus is situated close to the fourth ventricle and inside the ala cinerea as in the cases of most other mammals. Conspicuously marked is the distance between this nucleus and the hypoglossal nucleus because of the different location of the latter, which is observed to be in ventral apart from the fourth ventricle in this level in the sperm whale (Fig. 1, a).

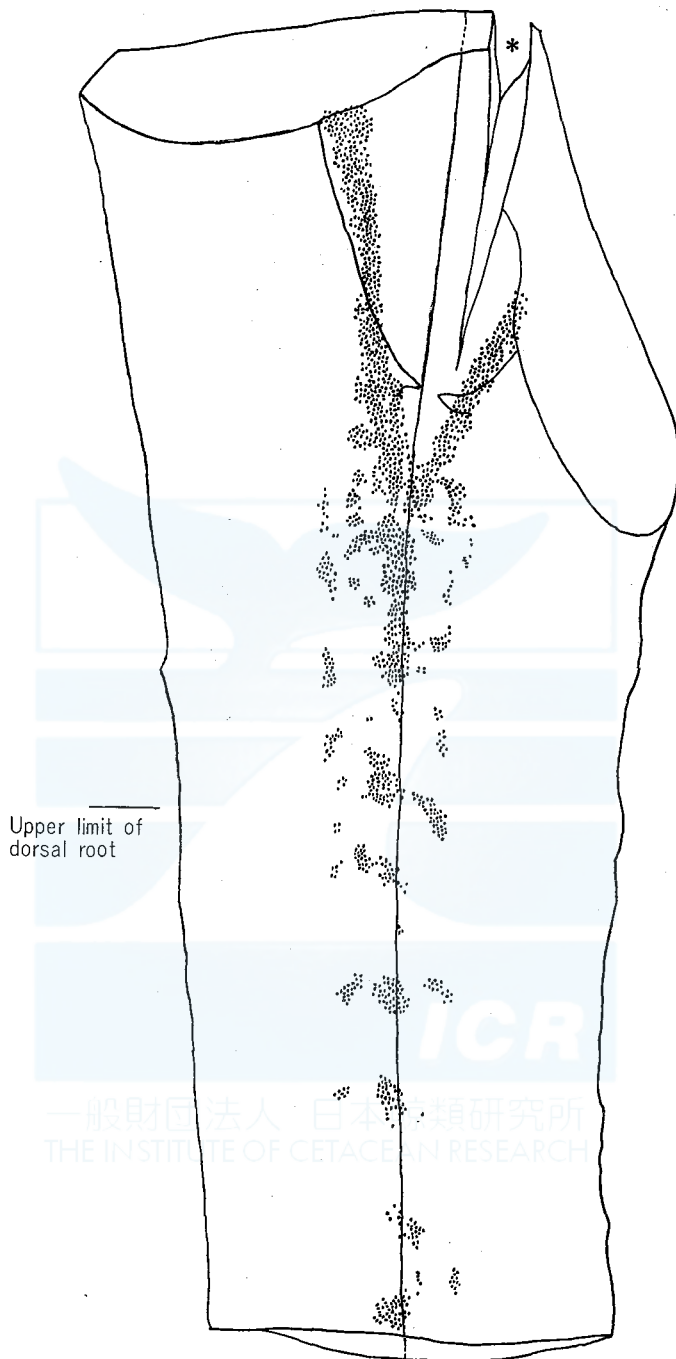


Fig. 3. Approximate distribution of cells superimposed from horizontal sections on the horizontal plane (dorsal view of the lower medulla and the 1st cervical cord) in case 2, Klüver-Barrera, $\times 4$. *: Artificial cleft.

In the part lower than the obex, the dorsal vagal nuclei on both sides are recognized to approach gradually toward the midline, and a small number of cells are observed to be existent sporadically between those two nuclei (Figs. 2 and 3). At this level also, the ventrolateral ends of these nuclei, extend in places near the bundle of accessory nerve root running longitudinally at the dorsomedial edge of the lateral funiculus, and tend to form a separate group at some distance of the main nucleus.

At the lowest medulla, these main nuclei completely fuse with each other, and form a transversely long cell group occupying a large area approximately in the middle of the central gray substance (Figs. 1b., 2 and 3). Beside this collection of cells, there are found here and there discontinuous cell groups, islands-like in appearance, in proximity of the accessory nerve roots running longitudinally at the dorsomedial margin of the lateral funiculus (Fig. 1, b). In other words, the dorsal vagal nucleus at this level can be distinguished in two parts; one is the main nucleus formed by fusion of the left and right nuclei into a medial cell group, and the other is the lateral one islands-like in appearance, and at the dorsomedial edge of the lateral funiculus. In certain other sections, these two groups of cells are observable to be in complete continuity.

The medial cell group, as it goes lower, is decreased in number of cells in sections from the lowest medulla to the upper cervical cord, until it presents a bead-like appearance. This can be traced as far as the first cervical level, together with the islands-like lateral cell group (Fig. 1, c). As has just been mentioned above, the materials available did not have the part lower than the second cervical cord, so that the further extension could not be identified.

DISCUSSION

As to the origin nuclei of glossopharyngeal, vagus and accessory nerves, two nuclei, ventral and dorsal, are distinguished. The former is situated at about the center of the reticular formation of the medulla oblongata, termed usually nucleus ambiguus, and innervates the striated muscle. The latter is located at the dorso-lateral or lateral to the hypoglossal nucleus, and has been thought to be the origin of the preganglionic fiber of the autonomic nerve which innervates smooth muscles and glands.

The dorsal vagal nucleus (or the dorsal motor nucleus of the vagus nerve) is clearly distinguished from its surrounding as a mass of middle sized nerve cells. Some authors call this dorsal vagal nucleus including termination nucleus (termed nucleus alae cinereae, on occasions) which is found immediately dorsolateral or lateral to that nucleus. It would be relevant to divide it into two and discuss separately instead of treating them as one entity: one as the termination nucleus consisting principally of small cells, another as the origin nucleus which is a group of the middle sized cells.

Olszewsky-Baxter (1954) and Mitchell and Warwick (1955) classified these nuclear cells into three types, but their classifications are different from each other, and neither of these seem to be applied to the materials in this study.

In the previous report (1966), I presented an idea to classify into four types the lowest structures of the dorsal vagal nucleus, after comparative anatomical investigations. In man, cat and rabbit, the lowest part of the nucleus decreases gradually cells in number as it goes downward and disappears at as low the level of the pyramidal decussation (type 4). The pacific right whale and the common dolphin also belong to this type. In the goat, the lower portion of this nucleus gradually shifts its position to the lateral side, across the pyramidal decussation or the internal arcuate fibers, and reaches the dorsomedial edge of the lateral funiculus of the upper cervical cord. This lower extension of the nucleus shows islands-like interruptions along the long axis of the spinal cord and disappears in the first cervical cord in common cases (type 1). Similar findings can be obtained in the calf, sheep, horse, camel, sea lion, dog and bear. In the pig, unlike those of type 1, two lower extensions are observed, one on the medial side and the other on the lateral side. At the lower medulla, the dorsal vagal nucleus is located at the dorsolateral to the central canal, and even in the portion lower than this level, extending cell groups can be traced intermittently in the same position until to the second cervical level, and in addition, as in case of type 1, laterally situated cell islands are still recognizable discontinuously along the dorsolateral edge of the lateral funiculus down to the second cervical cord (type 2). The medial cell group and lateral one are in direct continuity with each other in some sections, but in others there are found occasionally a bundle of thin fibers running between the two groups connecting them. In the case of the sperm whale, as in the pig, two lower extensions, medial and lateral, are identified, but unlike the finding in the pig, the medial cell groups on both sides are fused in the level from the lower part than the obex to the upper cervical cord, which is quite characteristic in the sperm whale (type 3).

Vermeulen (1915, 1916 and 1918) described that in llama, giraffe and porpoise, the dorsal vagal nucleus, at its lower end, constitutes the Nucl. commissuralis motorius vagi, by the fusion of two nuclei at the dorsal part to the central canal.

The lateral cell groups of the lower extension in three types, 1, 2 and 3, are well resemble the intermedio-lateral column (lateral horn nucleus) to develop into the thoracic cord, in respects of their position, size and massiveness of cells, and palely stained gray substance. These features were also noted in Takahashi's report (1913) on the comparative anatomy of the lateral horn nucleus. However, I have had no definitive evidence sofar that the dorsal vagal nucleus and the lateral horn nucleus of the thoracic cord are actually connected even in a stepping-stone-pattern. Similarly no reliable finding that the medial cell group is also connected with the intermedio-medial column at the former's lower part.

Of the lower extensions of the dorsal vagal nucleus, lateral cell group is positionally in a close relation with the accessory nerve root which runs longitudinally along the dorsomedial edge of the lateral funiculus, and it is imagined that these extensions send axons to this root. But the medial cell group did not give any special finding on a possible fiber connection, except there were observed bundles of thin fibers which connects the lateral cell group and the medial one in some sections.

As for the function of the lower extensions of the dorsal vagal nucleus, no

explanation or suggestion could be offered derived from these anatomical findings gained in this study. The utmost that can be deduced is the functions and the innervating areas to be inferred from those of the dorsal vagal nucleus, and no further.

CONCLUSION

A detailed anatomical examination was made on the dorsal vagal nucleus and its lower extension in 2 cases of the sperm whale. At the lower part of the nucleus, the lower extension consists of the medial cell group and the lateral one at the portion from the lower medulla to the first cervical cord. Characteristic is the fusion of the medial cell groups in both sides on the midline below the obex. In both cell groups gradually decreased cells in number as they go down and continue sporadically in islands-like appearance. The existence of the lower extension was not identified below the 2nd cervical cord.

Following the discussion on the structure of the lowest part of the dorsal vagal nucleus in other mammals, I could reconfirm that the lower extension of the sperm whale belongs to the type 3 in my previous classification.

REFERENCES

- MANNEN, H. and Y. SEKI, 1958. Quelques résultats d'observation de la partie supérieure de la moelle cervicale anatomie comparée. *Psychiat. et Neurol. Japon.* 60: 441-449.
- MITCHELL, G. A. G. and R. WARWICK, 1955. The dorsal vagal nucleus. *Acta Anat.* 25: 371-395.
- OGAWA, T. and Y. CHEN, 1947. On the direct continuance of the dorsal vagal nucleus and the lateral horn nucleus of the spinal cord. *Kaibogaku Zasshi (=Acta Anat. Nippon.)*, 23, 9. Proceedings of the 51st meeting of the Japanese Association of Anatomists (in Japanese).
- OLSZEWSKI, J. and D. BAXTER, 1954. *Cytoarchitecture of the human brain stem.* Karger, Basel. 199 pp.
- SEKI, Y., 1966. Comparative anatomical studies on the lower extension of the dorsal vagal nucleus to the upper cervical cord. *Anat. Rec.* 154: 421. Abstracts of 79th session of the American Association of Anatomists.
- TAKAHASHI, D., 1913. Zur vergleichenden Anatomie des Seitenhorns im Rückenmark der Vertebraten. *Arch. Neurol. Inst. Wien. Univ.* 20: 62-83.
- VERMEULEN, H. A. 1915, 1916 and 1918. Cited from KAPPERS, C. U. A., G. C. HUBER and E. C. CROSBY, 1936. *The Comparative anatomy of the nervous system of vertebrates, including man.* Vol. 1. Macmillan, N. Y. 864 pp.


一般財団法人 日本鯨類研究所
THE INSTITUTE OF CETACEAN RESEARCH

EXPLANATION OF PLATE I

- Fig. 1. Lower medulla below the obex (Section number 130 of block 2, Case 1), Kultschitzky, $\times 6$.
- Fig. 2. First cervical cord (Section number 261 of block 1, Case 1), Klüver-Barrera, $\times 40$.
 → ←: Midline.

Abbreviations in Text-figure 1 and Plate.

CA	Anterior horn	NA	Nucleus ambiguus
CP	Posterior horn	NDV	Dorsal vagal nucleus
FLM	Medial longitudinal fascicle	NFP	Nuclei of posterior funiculi
FS	Solitary fascicle	NNXII	Hypoglossal nucleus
LCG	Lateral cell group of the lower extension	NTDV	Nucleus of descending tract of the trigeminal nerve
MCG	Medial cell group of the lower extension	RNXI	Accessory nerve root
		VQ	Fourth ventricle



一般財団法人 日本鯨類研究所
 THE INSTITUTE OF CETACEAN RESEARCH

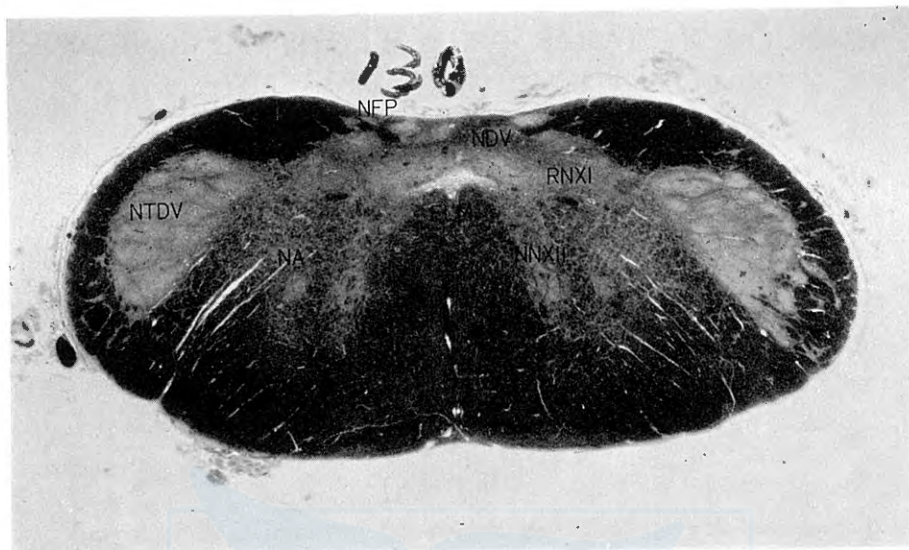


Fig. 1




Fig. 2