

PRENATAL DEVELOPMENT OF EAR PLUG IN BALEEN WHALES

TADAYOSHI ICHIHARA

The ear plug is a fairly soft tissue existing in the external auditory meatus of the Mysticeti. It is composed of independent two tissues derived from the epidermis of external auditory meatus and from that of so-called glove-finger. The glove-finger projects outwards from the tympanic bulla into the external auditory meatus. Since Purves (1955) found out ring-like laminae in the longitudinally bisected plug-core derived from the epidermis of the glove-finger, the plug-core has enchanted many cetacean biologists interested in determining the age of whales. Counting the ring-like laminae to evaluate age of baleen whales is no more than understanding life histories of these whales through their ear plugs.

As series of studies on ear plugs, I have much interested in the formation of ear plugs in the prenatal stage, because animal tissues begin to develop from the prenatal period and the epidermis of the glove-finger also belongs to the same growth category. It was also necessary to confirm my previous finding (Ichihara, 1959) through the many materials from the baleen whale fetuses. In this paper, I examine the morphology and histology for the prenatal development of the glove-finger along with the ear plug. The keratinized and fatty degeneration of epidermal cells of the glove-finger are alternately accumulated to form the plug-core in the postnatal stage of the baleen whale. The present study not only supports this fundamental mechanism found by me, but also gives some suggestions to interpret the factors affecting the formation of the plug-core.

I am much indebted to Dr. Hideo Omura, the Director of our Institute for his kind support throughout this work. My sincere thanks are due to Messrs. Toshitomo Shida and Yasuji Fukuda, the Department of Anatomy, Faculty of Medicine, University of Tokyo, for their kind helps in the histological examination and photomicrographic technique. I also indebted to Dr. Kazuo Fujino, a staff of our Institute, who collected several heads from fin whale fetuses in the Antarctic expedition and brought them to my study.

MATERIAL AND METHOD

Most of materials in this paper were collected by myself on board Nisshin-maru, a factoryship of Taiyo Gyogyo Company in the Antarctic expedition in the 1959/60 season. Fetuses were taken from the uteri of flensed mother whales. After measuring the lengths of fetuses, their heads were cut off and pieces available for this study, that is, posterior portions of heads including the external auditory meatus, glove-finger and tympanic bulla were obtained. These specimens were preserved in the 10% formalin solution soon after this treatment. The large blocks from full-grown fetuses are preserved in diluted formalin solution under 10% as the first step and

removed gradually into concentrated solution for the examination at our Institute. In the same way Dr. Fujino kindly presented me several heads from fin whale foetuses in the Kyokuyo-maru No. 2 expedition in the 1960/61 Antarctic season. These specimens are used to check my interpretation. The examined specimens which I collected comprise 48 Antarctic fin whale (*Balaenoptera physalus*), 17 sei whale (*Balaenoptera borealis*) and 2 humpback whale (*Megaptera novaeangliae*) foetuses as presented in the appendix.

Law's finding (1959) for the foetal growth curve is applied to determining accurate foetal months from the lengths of examined foetuses. According to Laws the average duration of gestation is 11 1/4 months for the Antarctic fin whale and about 12 months for the North Pacific sei whale.

I counted numbers of ovulation in mother's ovaries at the spot aboard the factory ship to evaluate the relative age of the mother whale. The examined foetuses are obtained from mother whales of various ages and there is no bias in the sampling, in which I intended to obtain the foetuses of various length. The specimens from foetuses under 71 cm, corresponding to the 3 3/4 foetal months, also were obtained but failed to be examined in the sectioning course. These blocks from heads were dissected for the morphological study. Later glove-fingers and ear plugs were embedded in the celloidin solution, and sectioned in the thickness from 10 to 15 μ . The staining method by haematoxylin eosin was applied.

The post-mortem times range from 1 hour and 25 minutes to 13 hours and 35 minutes for the foetuses of fin whales, from 45 minutes to 9 hours and 40 minutes for the sei whale foetuses, and from 3 hours and 45 minutes to 7 hours and 5 minutes for the humpback whale foetuses, as listed in the appendix. In addition to the specimens from such foetuses, I examined the prenatal layers of ear plugs from adult baleen whales, which also includes the blue (*Balaenoptera musculus*), the Bryde's (*Balaenoptera edeni*) and the minke whale (*Balaenoptera acutorostrata*).

MORPHOLOGY OF GLOVE-FINGER AND EAR PLUG

In the course of dissecting the external auditory meatus of foetuses from the ear hole to the tympanic bulla through the blubber, I observed the colour on the surface of auditory meatus and glove-finger and then measured the length of space from the blind section beneath the blubber to the distal end of the glove-finger. Taking the glove-finger out of the auditory meatus, I measured the length of glove-finger, from its distal end to the proximal end of tympanic ligament, and its breadth.

From the colour on the surface of glove-finger and from that on the internal wall of external auditory meatus, four stages are present in the foetal stage of the baleen whale as indicated in Table 1. In fin whales, stage I indicates the development until the 3rd and 4th foetal months, stage II the 5th and 6th foetal months, stage III from the 7th to 9th months and stage IV after the 10th foetal months. In sei whales, stage II represents the 5th to 7th foetal months. Glove-fingers of foetuses in stage I are transparent and rather whiter. From stage II to III their colours change from pinkish-white to dark-brown. In stage IV, glove-fingers of

fin whales are brown, while those of sei whales do gradually black. Ear plugs from adult sei whales is more black than that from fin whales. The content of melanin during the keratinized degeneration of epidermal cells probably is more abundant for the sei whale than for the fin whale. The colours of stage IV are maintained from juvenile to adult both for fin whales and for sei whales. The observation for foetuses of the humpback whale is insufficient for describing the colour change during foetal development but glove-fingers are pinkish-white in stage II.

TABLE 1. COLOUR OF GLOVE-FINGER, EXTERNAL AUDITORY MEATUS AND BLIND SECTION FOR EACH FOETAL MONTH OF THREE SPECIES IN THE BALEEN WHALE

FIN WHALE				
Stage	Pregnancy month	Glove-finger	External auditory meatus	Blind section
I	3	White (transparency)	White	—
	4	"	"	—
II	5	Pinkish-white	Pinkish-white	—
	6	"	"	—
III	7	Light-brown	Light-brown, Black antero-dorsal portion	—
	8	Dark-brown	Dark-brown	Yellow
	9	"	"	Yellowish-white
IV	10	Dark-brown	Dark-brown	"
SEI WHALE				
Stage	Pregnancy month	Glove-finger	External auditory meatus	Blind section
II	5	Pinkish-white	Pinkish-white	—
	6	"	"	—
	7	"	" , Black antero-dorsal portion	—
III	8	Light-brown	Light-brown	—
	9	Dark-brown	Dark-brown	—
IV	10	Black	Black	—
HUMPBACK WHALE				
Stage	Pregnancy month	Glove-finger	External auditory meatus	Blind section
II	6	Pinkish-white	Pinkish-white, Black antero-dorsal portion	—

The colour on the internal wall of external auditory meatus is very similar to that on the surface of the glove-finger but it becomes black at stage III particularly in the antero-dorsal portion. The black portion tends to extend gradually to other part of the external auditory meatus. The black part occurs in stage II for sei and humpback whale foetuses.

In the early foetal month, the colour on the surface of glove-finger depends on the thickness of connective tissue and the abundance of blood capillaries or blood vessels. However the brown colour over stage III indicates the occurrence of adhesive materials on the surface of the glove-finger and of the internal wall of the external auditory meatus. In fact, the original colour of the glove-finger and the external auditory meatus appears again after scraping these materials off. From

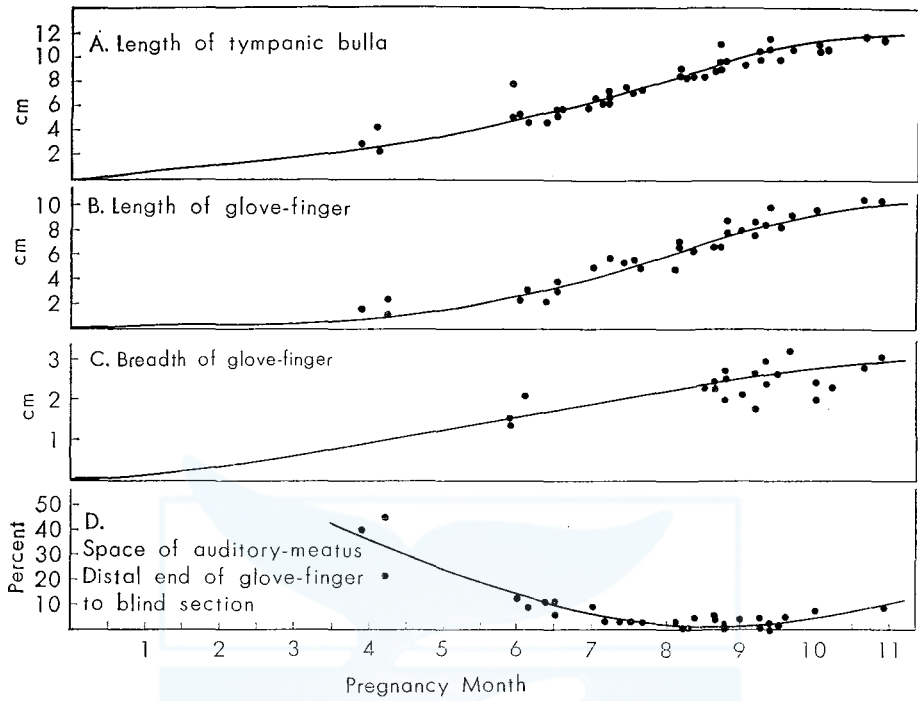


Fig. 1. Growth of tympanic bulla, glove-finger and external auditory meatus in the fin whale foetus from the Antarctic.

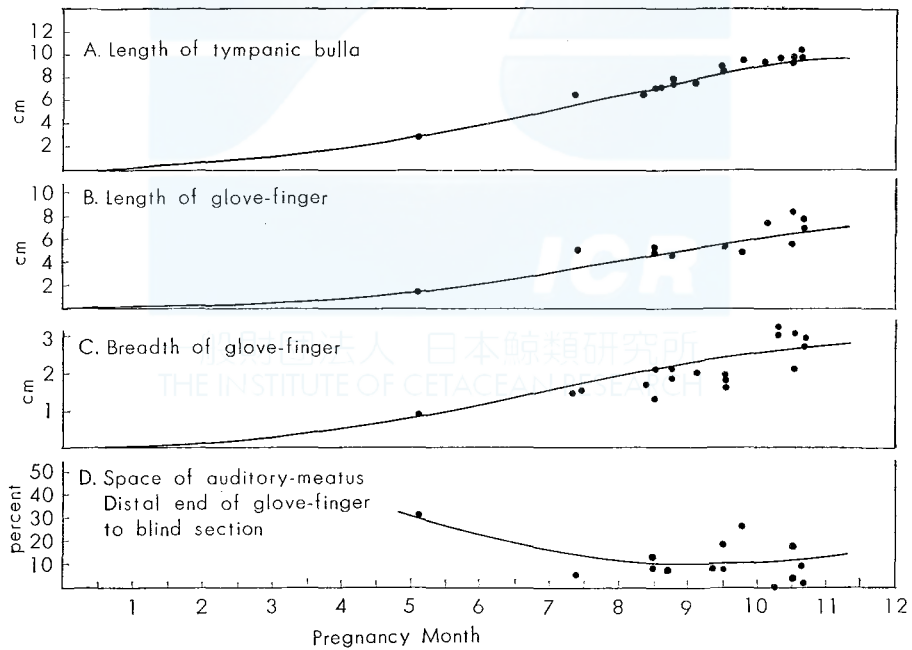


Fig. 2. Growth of tympanic bulla, glove-finger and external auditory meatus in the sei whale foetus from the Antarctic.

the naked-eye observation, the horny layer of foetal epidermis seems to be accumulated from 7th foetal month for fin whales and from about the 8th foetal month for sei whales. In fin foetuses, the yellow adhesive materials are observed on the blind section of the auditory meatus over the 8th foetal month. These materials develop into ear plugs and observed by the naked-eye as various shapes in the latter half of the 9th foetal months.

To examine the transformation of the glove-finger, its length and greatest breadth were measured. The measurement of the distance from the distal end of the glove-finger to the blind section of the external auditory meatus was needed for examining the mechanism which the prenatal ear plug is preserved throughout the life span of whale. Fig. 1 indicates the relation between the development of the glove-finger and that of the external auditory meatus. The shape of glove-finger changes from the early to the late foetal stage. The length of glove-finger from its distal end to the end of tympanic ligament increases rapidly after 4th or 5th foetal months for the fin and sei whale. Until the middle foetal stage, the greatest breadth is indefinitely measured but estimated to grow in the same way as the increment of length. As shown in Fig. 1, the length of tympanic bulla, which is a bony tissue closely connected with the glove-finger, also increases in a sigmoid curve in the foetal stage. The size of the tympanic bulla seems to increase slightly in the postnatal stage, while the growth of the glove-finger is completed in the late foetal stage. Although the size of the sei whale glove-finger is different from that of the fin whale, the growth pattern is about the same between two species (Fig. 2). This observation may be applied to the other baleen whales.

The relation between the glove-finger and the external auditory meatus is of most importance to pursue the prenatal development of the ear plug. In fin whale foetuses the space between the blind section of the external auditory meatus and the glove-finger is large in the early stage. At each foetal month, the relative value of the space changes as indicated in the lowest in Figs. 1 & 2. The space in these figures represents the length from the distal end of the glove-finger to the blind section of the external auditory meatus. If the relative value of the space is expressed as a percentage of the length of the auditory meatus from the proximal end to the blind section, it distributes along the concave curve with the developing foetal month. The external auditory meatus is closely connected with the glove-finger at its proximal end. In fin whales the relative space exceeds 40 percent under the 4th foetal month and approaches to zero percent from the 8th to 9th foetal months, when some foetuses have no space between the blind section and the glove-finger. In the late foetal month, it increases again and is supposed to extend rapidly at the postnatal stage. In fact the external auditory meatus of the adult whale is elongated along the squamosal region of the large skull. This change of space also is drawn in Fig. 3.

On the other hand the sei whale foetus has a fairly larger space in the 8th, 9th and 10th foetal months, compared with the fin whale foetus. The space is 10 percent in these foetal stages, as shown in the lowest of Fig. 2 and there is only one foetus having no space. The change of space in Fig. 1 & 2 represents an evidence that the development of the external auditory meatus is not proportionate to that

of the glove-finger in the foetal stage. In two humpback whale foetuses, relative values of spaces are 29.6 and 44.4 percent but these foetuses are in the 6th foetal months. This evidence probably is expanded for the other species of the balaenopterid whale than fin, sei and humpback whales.

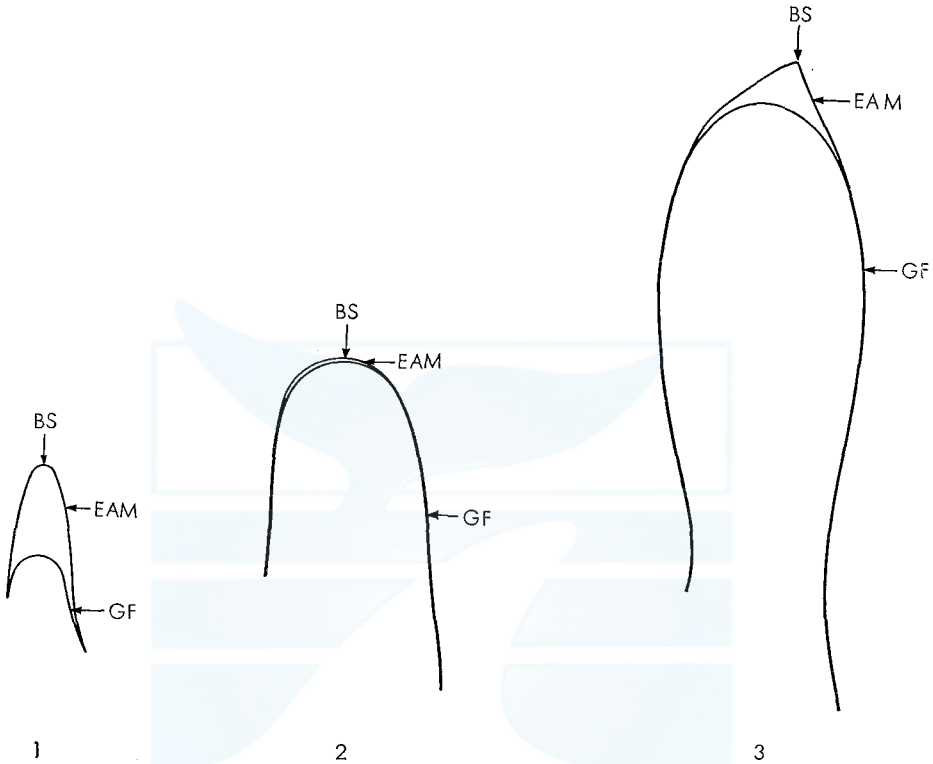


Fig. 3. Relation between the glove-finger and the external auditory meatus in the developing foetus of the fin whale.

1. The 4th foetal month BS : Blind section
2. The 7th foetal month EAM : External auditory meatus
3. The 10th foetal month GF : Glove-finger

In fin whale foetuses the external auditory meatus becomes to cover the outside of the glove-finger after the keratinized epidermal cells was accumulated. Therefore, the prenatal plug-core of the fin whale is surrounded by the keratinized layer derived from the epithelium of the external auditory meatus. The mechanism that the prenatal ear plug is preserved for the all life of fin whales is interpreted from this finding. In most of sei whale foetuses, the external auditory meatus does not surround the surface of the glove-finger throughout the foetal stage. The prenatal ear plug, therefore, is unstably accumulated. In fact, it is very difficult to find the prenatal layer in the ear plug from the adult sei whale. At the distal end of the plug-core, it is easily separated from the outer covering. The practical collection of whole ear plugs to evaluate the age is difficult for the sei whale.

From the presence of the prenatal ear plug and space of the external auditory meatus, baleen whales are divided into two categories. The one includes the ear plugs from blue, fin, Bryde's and humpback whales. In the most of these whales, prenatal ear plugs are preserved completely throughout the life span. The other contains the ear plugs from sei and minke whales, in which prenatal layers are indistinguishable. In the former category, the shape of prenatal ear plug depends upon the shape of space between the glove-finger and the internal wall of the external auditory meatus near the full foetal month. I draw the shape of the prenatal ear plug of the fin whale in Fig. 4. The ear plugs accumulated at the distal end of the glove-finger develops according to the shape of the increasing space after the 8th foetal months.

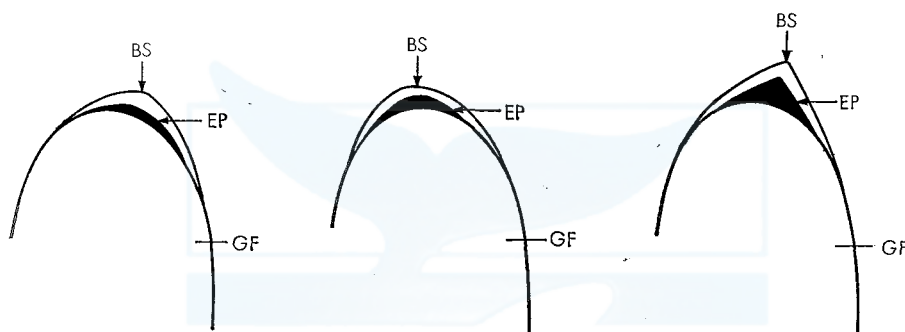


Fig. 4. Shapes of ear plug in the late foetal stage of the fin whale. It correlates with the shape of space from the distal end of glove-finger to the blind section of external auditory meatus.

- BS: Blind section of external auditory meatus.
- EP: Ear plug.
- GF: Glover-finger.

There are various kinds of shapes in the prenatal ear plugs. The most dominant shape is crescent and the triangular shape sometimes present. Such a finding is applied to blue, Bryde's and humpback whale foetuses. In the ear plugs from adult blue, Bryde's and humpback whales there remain various shapes of prenatal layers.

HISTOLOGY

The study on the formation of prenatal ear plug should be approached by the histological examination. When age of baleen whales are estimated by ear plugs, the core part is more important than the outer-covering (Purves, 1955), although the core and outer-covering constitute so-called ear plugs of baleen whales. The histological examination in this paper, therefore, was focused on the plug-core derived from the degenerated epidermal cells of the glove-finger. Ichihara (1959) points out that the celloidin section suits for the hard materials like the glove-finger and the frozen section for the soft materials like the ear plug. In the foetal stage, how-

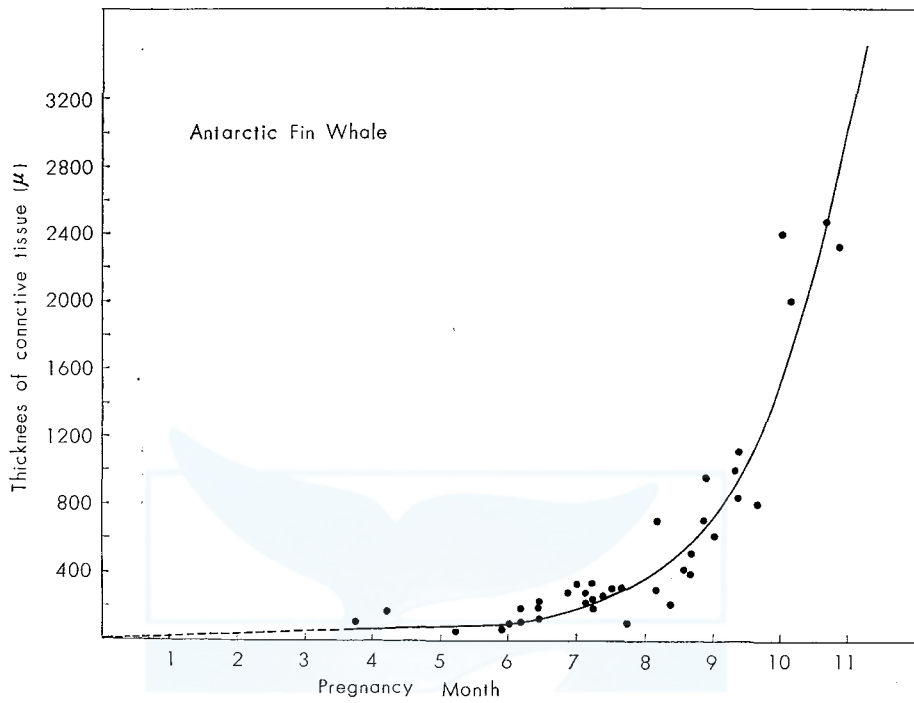


Fig. 5. The increasing thickness of the connective tissue of the glove-finger from the fin whale fetus. The broken line is estimated.

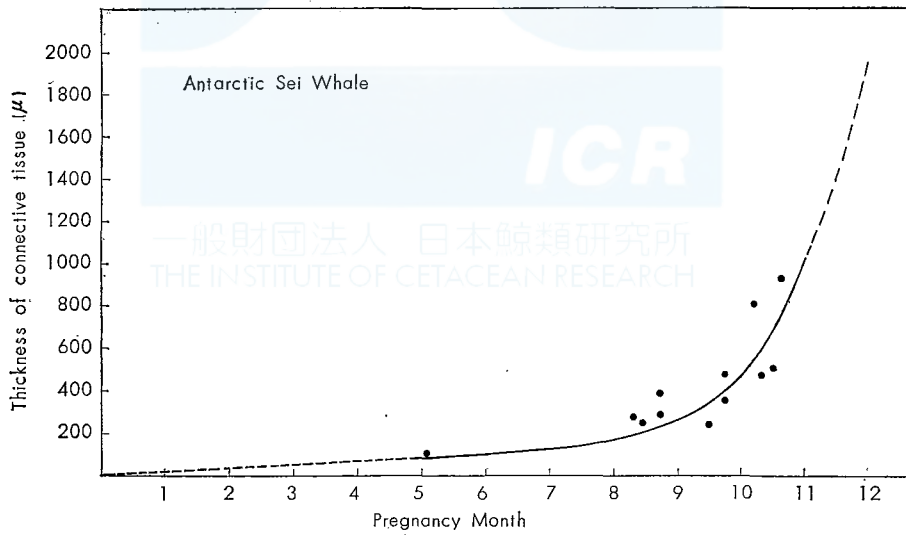


Fig. 6. The increasing thickness of the connective tissue of the glove-finger from the sei whale fetus. The broken line is estimated.

ever, very thin ear plugs are accumulated on the surface of the glove-finger, and hence I used only the celloidin section for this study. On the basis of the section of thickness from 10 to 15 μ , I measured the thickness of the connective tissue of the glove-finger, that of the keratinized layer and fatty degenerated layer of the glove-finger epidermis for each specimen. My observations also are made for the degeneration of nucleus of the germinal layers and for the occurrence of the keratinized layer densely stained by eosin.

Thickness of connective tissue: The thickness of the connective tissue was measured between the basal layer of the outer epidermis and that of the inner one of the glove-finger. As papillary layers undulate slightly after the 6th foetal months, the mean value is obtained from several measurements for each specimen. The thickness of the connective tissue is plotted against each foetal month of the fin whale as shown in Fig. 5. The broken line is estimated in the figure, because available data are insufficient. There is a suitable straight line for the increasing thickness until about the 6th foetal month and then the thickness grows rapidly until the full foetal month. Just after birth, the thickness of the connective tissue approaches to about 2900 μ , the mean value for the adult fin whale.

The thickness of the connective tissue represents the same increment for the sei whale foetus but it is thinner than for the fin whale foetus as, indicated in Fig. 6.

Keratinization: A specimen from the 3 3/4 to 4th foetal months is covered with two layered epidermis. The outer layer, the periderm, constitutes a protective covering although the nucleus is in a depressed form (see Plate I, Fig. 1). The basal layer of early embryo is composed of low cuboidal cells with clearly stainable nuclei and a smooth basal surface. With the increasing embryo, the basal cells become columnar with large, darkly stained nuclei and proliferative. Even in a specimen from the 3 3/4 to 4th months, the compact basal layer is covered by periderm cells, some of which are exfoliating.

In the human embryo, a stratum intermedium, proliferated from the basal layer develops between the basal layer and periderm at about the 4th foetal months and toward the end of foetal life it, now called stratum spinosum, or prickle cell layer, is several cells thick (Montagna, 1962). These processes also exist in the epithelium of baleen whale foetuses.

The periderm of the foetal glove-finger is stained lightly by eosin. Montagna (1962) states that the keratohyalin granules appear where the epidermis is thickest but the general epidermis has no stratum granulosum at the end of the 5th months in the human embryo and that the keratinization progresses only when the stratum granulosum is formed. The stratum granulosum is not observed definitely in the thick epidermis of the glove-finger from the baleen whale, although it is assumed that the same mechanism as in the man progresses in the keratinization of the whale epidermis.

To examine when the keratinization begins, I measured the thickness from the upper edge of the basal layer to the most distal end of accumulated substance for each specimen from fin whale foetuses and plotted it against each foetal month in Fig. 7. The thickness expressed in such a way certainly includes both the kera-

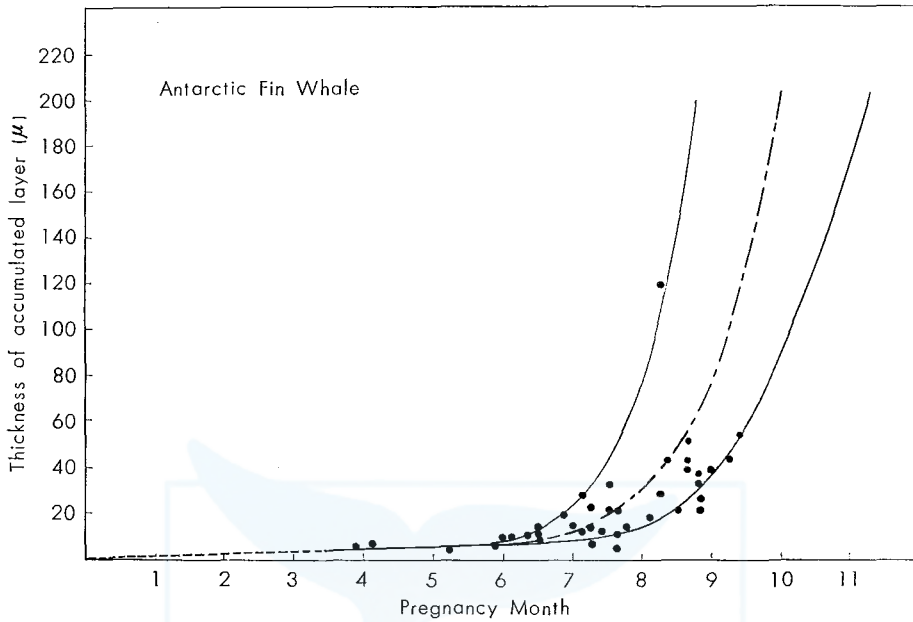


Fig. 7. The increasing thickness of the accumulated layer of the fin whale foetus, including the keratinization and the fatty degeneration layer in the epidermis of the glove-finger. Broken line is estimated and chain line indicates the mean curve.

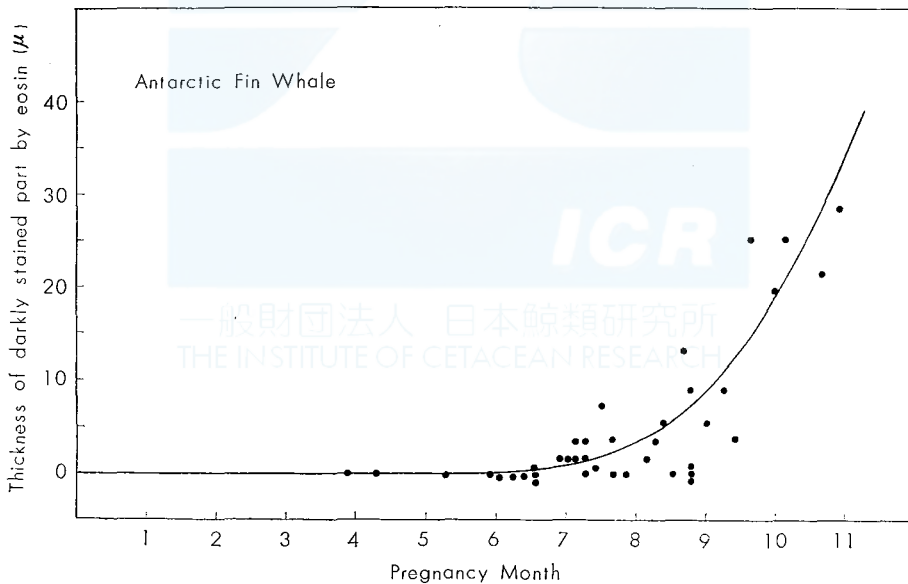


Fig. 8. The increasing thickness of darkly stained part by eosin with the advancement of the foetal month of the fin whale. This part is present at the lowest of keratinized layer.

tinized layer and the fatty layer described later. Therefore, the thickness of keratinized layer will be obtained by subtracting the fatty layer from total accumulated layer. It is difficult to examine accurately the primitively keratinized cell from the prickle cell layer in the late foetal stage.

Fig. 7 indicates the accumulation speed in the fin whale foetus. From fertilization to the 6 1/2 foetal months, the accumulation progresses in a constant ratio, although it is estimated by the broken line in the early foetal stage from fertilization through the 3rd foetal month. After the 6 1/2 foetal months, the accumulated layer is rapidly thick but there are great variations for individual specimens. An accumulated layer from one specimen of the 8 1/4–8 2/4 foetal months is 119 μ thick, while that from another specimen of the same foetal month is 28 μ thick. As the external auditory meatus covers the surface of the glove-finger after the 8th foetal months, it is difficult to examine the whole accumulated layer only from sections of glove-fingers. The prenatal ear plug, disconnected from the surface of glove-finger, indicates various heights. The values of the keratinized layers are about 4300 μ for a specimen from the 9 2/4–3/4 foetal months, about 850 μ for that from the 10–10 1/4 foetal months and about 3800 μ for that from the 10 3/4–11 foetal months.

These variations probably depends on the activity of the mitotic division on the prickle-cell layer or the basal layer of the epidermis. There are also great variations for the lengths of plug-cores from adult fin whales (Nishiwaki, Ichihara & Ohsumi, 1958; Purves & Mountford, 1959).

The germinal layer also becomes thick rapidly after the 6th foetal months and is maintained for the late foetal month. Probably the thickness of the germinal layer and hence the number in stratified cells, also will be kept in the postnatal life.

At the same, the layer stained darkly by eosin begins to occur in the distal end of the accumulated layer as indicated in Plate II, Fig. 1 & III, Fig. 1. This darkly stained layer is thick with the growing foetuses and reaches about 40 μ in thickness at birth. The increment of this layer for examined specimens is plotted against each foetal month of the fin whale in Fig. 8. Although the periderm in the early foetal stage appears to undergo cornification, it probably does not mean the keratinization. The occurrence of darkly stained layer seems to indicate the keratinization in the epidermis of the glove-finger.

In the sei whale foetus as well as in the fin whale foetus, the darkly stained layer occurs when the accumulation ratio increases rapidly. Fig. 9 shows the increasing thickness of total accumulated layer against each foetal month of the sei whale, although available specimens are insufficient. The keratinization in the epidermis of the glove-finger arises at the 8 1/2 foetal months of the Antarctic sei whale.

For the sei whale foetus, there is a divergence between the growth curve by obtained by Matthews (1938) and that indicated by Laws (1959). Interpretation by Matthews results from the Antarctic sei whale, while Laws has his conclusion on the basis of the North Pacific sei whale, therefore, the divergence may be derived from the localities of sei whales. In determining the foetal month of the sei whale, I adopted Laws' finding, because his curve fits the growth patterns of other balaenopterid whales. I am afraid, however, the keratinization for the Antarctic

sei whale foetus occurs slightly earlier than the 8th foetal month. There are also great variations in the thickness of the keratinized layer for the individual foetus of the sei whale. In the 10 1/2 foetal months, an accumulated layer from a specimen is 273 μ thick, while that from another specimen is 35 μ thick.

The keratinized layer in the foetal stage remains in the ear plug of the adult baleen whale. Plate V indicates the presence of the prenatal keratinized layer, appearing at the most distal end of the plug-core, outside of the prenatal fatty layer for various baleen whales. The prenatal keratinized layer is observed more clearly in the fin, blue, Bryde's and humpback whale than in the sei and minke whale.

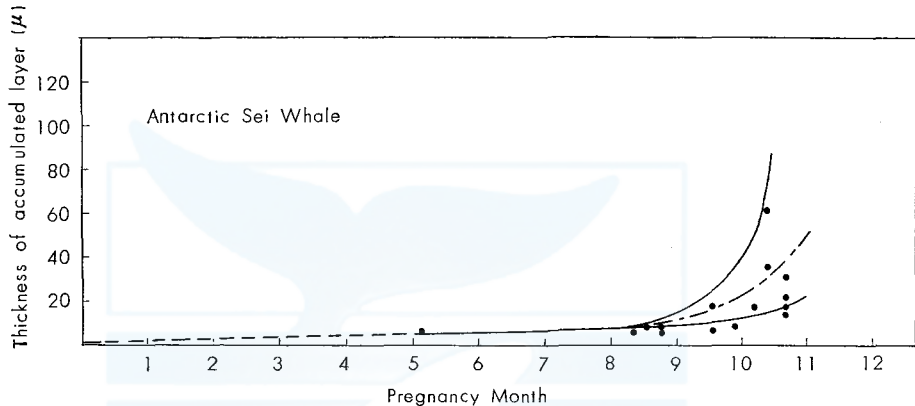


Fig. 9. The increasing thickness of the accumulated layer of the sei whale foetus, including the keratinatin and the fatty degeneration layer in the epidermis of the glove-finger. Broken line is estimated and chain line indicates the mean curve.

Fatty degeneration: The germinal layer becomes thick with the advancement of the foetal month and composed of cells in several layer at the 6 1/2 foetal months. The outside prickle-cell layer continue to degenerate into the keratinized cells from the 6 1/2 to the 8th foetal months, when slightly swelled cells in the prickle-cell layer sometimes contain lipoid granules in their cystopasms. This indicates the occurrence of fatty degenerated cells in the epithelium of the glove-finger. The fatty degeneration progresses rapidly in the whole prickle-cell layer in larger foetuses after the 8th foetal months. The cystoplasms filled with lipoid granules develop into the fatty layer which is removed outwards by the pressure of newly degenerated fatty cells. The accumulation processes of fatty layers are clearly indicated in Plate III, Fig. 1 & 2 and IV, Fig. 1 & 2. From the 10th to 11th foetal months of the fin whale, the fatty layer is from 33 μ to 130 μ thick and estimated rapidly thick at birth.

As the fatty layer remains on the surface of glove-finger, its thickness can be measured accurately through the section. Fig. 10 indicates the increment of fatty layer against each foetal month of fin whales. The thickness of the fatty layer is measured between the lower border of the keratinized layer and the basal layer of the glove-finger epidermis. According to this figure, the fatty degenerated cells

appears at the 8th foetal months and the fatty layer develops over 180 μ in thickness for 3 1/4 month until the birth of the fin whale foetus. Through the microscopic examination, my previous finding (1959) can be applied to the process of fatty degeneration in the prenatal ear plug. This suggests that the fatty degeneration passes through the same mechanism in the prenatal as well as in the postnatal ear plugs.

In specimens from sei whale foetuses, fatty granules are found for the first time in the cytoplasm of degenerated cells in the 10 1/4 foetal months. Although a few specimens do not represent the rigid finding, it is assumed that sei whale foetuses develop more thin fatty layer than do fin whale foetuses.

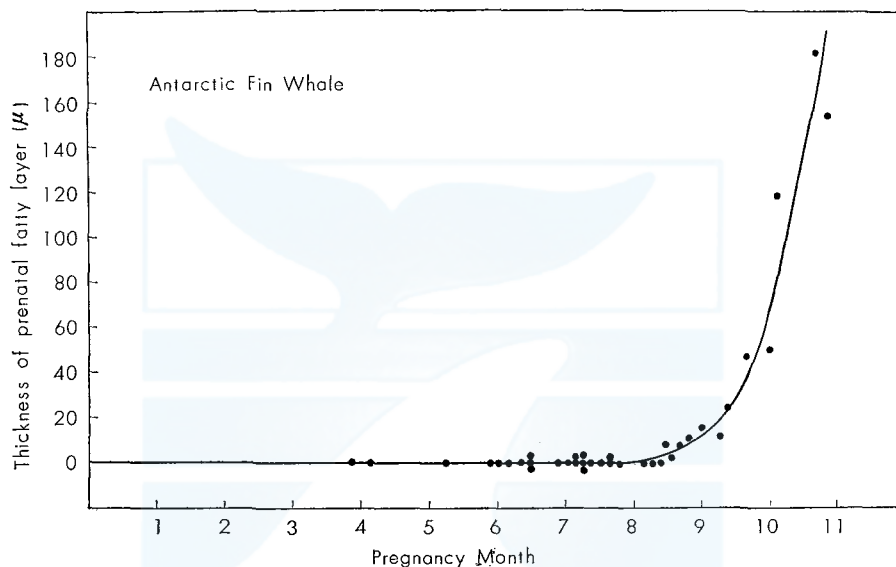


Fig. 10. The increasing thickness of the prenatal fatty layer of the fin whale, composed of fatty degenerated cells in the epidermis of the glove-finger.

By the naked eye observation, these fatty layers remain at the distal end of all ear plugs from fin, blue, Bryde's and humpback whales, therefore, it can be recorded by the photometric method (Ichihara, 1962). Prenatal fatty layers of ear plugs from various kind of baleen whales are indicated Plate V ; Figs. 1, 2, 3, 4 & 5.

The longitudinal fatty layer is absent in the keratinized layer of the prenatal ear plugs. In the bisected specimen of the ear plug from the adult baleen whale, the longitudinal fatty layer is clearly present at the concavity in the epidermis corresponding to the undulate papillae in the derma of the glove-finger. In the postnatal ear plug, furthermore, the longitudinal fatty layer becomes more clear near the proximal end with the advancement of the whale age. This is primarily because the papillae of derma project outwards with the increasing age of the whale, although there are individual variations in its degree. The absence of the longitudinal fatty layer in the prenatal stage is based on not only the comparatively flat surface of papillae but also the unique process in which the keratinized fusiform cell is nearly

the same size as the fatty degenerated cell. This feature is shown in Plate IV, Fig. 2. The transformation of degenerated cell in the ear plug from the adult whale was already described (see Fig. 9, Ichihara, 1959). The physical force during the development of ear plug effects intensively on the formation of the longitudinal fatty layer. This will be examined in connexion with the renewal time of epidermal cells in the future study.

DISCUSSION

Laws & Purves (1956), examining ear plugs from young fin whale captured at the norwegian coast, confirm their earlier conclusions about initial stages in the formation of the plug. They continue their statements that the first lamination which is always a small, conical, unstratified body rich in calcium, is deemed to be that part of the plug which is present in the ear before birth. It is vague what they mean by the first lamination, but the unstratified body probably indicates only the fatty layer described in the previous chapter of this paper. There are, however, two layers in the ear before birth, composed of dark and bright layers.

Chittleborough (1959) reports that only the secretory membranes were found when the ear plugs from near-term humpback whale foetuses were dissected out, and he considers that the first lamination of the ear plug is laid down soon after birth. Although he disagrees with the presence of prenatal ear plug in the humpback whale, I suppose that his finding depends on examining the surface of the glove-finger on which the collapse of prenatal keratinized and fatty layer has already progressed. With the increasing time from kill to flensing, the new ear plug rich in keratin undergoes decomposition and hence it is disconnected from the surface of the glove-finger, even in adult baleen whales. I confirmed the presence of the prenatal ear plug for a near-term humpback whale foetus taken off Ryukyu Islands, as reported in my previous paper (Ichihara, 1959). Besides in this paper I reconfirm the occurrence of degenerated epidermal cells in glove-fingers from two Antarctic humpback whale foetuses. Crisp (1963) discusses the effect of adult whale length and post-mortem time on ease of removing ear plugs from fin whales and concludes that there is a significant difference in the success of extraction between the whales with post-mortem times of less than 7 hours and those that had post-mortem times of more than 7 hours. There is a positive relationship between the ease of removing ear plugs and the decomposition of their tissues, however, the technical ease is different from the accurate examination on the ear plug. Histological examinations need the fresh materials.

The development of baleen plate should be noticed here. The periodic growth of the cortical layer sheathing the medullary layer in the baleen plate has been an indicator of age of baleen whales since Ruud (1940) pointed its significance. The cortical layer is formed by the cornification of cells from the lateral surfaces of the blade-pulp, while the medullary tissue is formed from the lower and inner margin (Eschricht & Reinhardt, 1866 ; Tullberg, 1883). Citing Tullberg's paper, Mackin-

tosh and Wheeler (1929) states that the first rudiments of the two blocks of baleen plate are found after the blue whale foetus reaches a length of 2 metres or more and then two plain strips of a soft whitish material appear, one on each side of the upper jaw. They state, furthermore, that at the 2.5 to 3 metres, minute transverse ridges appear on these strips and later develop into whalebone plates. With regard to fin whales, Mackintosh & Wheeler describe that the development of the baleen in the blue whale foetus applies equally to its development in the fin whale foetus. Ohsumi (1960) reports that the first rudiments of the baleen plates are found at the length of 1.75 metres in the Antarctic fin whale foetus.

According to the foetal growth curve of baleen whales, indicated by Laws (1959), the length of 2 metres in the blue whale and that of 1.75 metres in the fin whale correspond to the 7th foetal months. The occurrence of rudiments of baleen plates does not yet indicate the keratinization of cells from lateral surfaces of the blade-pulp.

The evidence that the keratinized cells in the epidermis of the glove-finger appears at the 6 1/2 foetal month of the fin whale supports the finding that steps in the prenatal development of keratinized cells depend on various tissues of the whale body. The keratinization might be more precocious in the epidermal cells of the glove-finger than those of the other tissues, however, it is necessary to reexamine the significance underlying in the comparison between the periodic mark on the baleen plate and the laminae number in the ear plug, because these two age indicators for baleen whale is formed primarily from the keratinization of cells.

In the prenatal stage of fin whale, the fatty degenerated cells appears from the 8th foetal months and develops until birth. The prenatal fatty layer in the other baleen whale enables us to discriminate it from the postnatal accumulation of the ear plug. A sudden turn of the epidermal cells from the keratinized to the fatty degeneration can not occur without the internal stimulation of the body. In the foetal stage, it is the most reasonable to accept the endocrinal stimulus through the blood supply from the maternal body. Although enzymes act as catalysts in the regulation of metabolic processes, hormones *in vivo* exert their influence by acting indirectly upon the enzymes which catalyze the particular reaction (Rothman, 1954).

The season when the fatty degeneration arises in the maternal ear plugs will be examined in relation to the physiological rhythm in the future study, through which the relation between the biological clock and the calendar period will be clarified.

The neonatal line of the ear plug is defined as the part where the formation of the prenatal fatty layer ends.

SUMMARY

In the course of my continuous study on the accumulation of the ear plug, the most reliable material to determine the age of baleen whales, I examined the prenatal development of ear plug by using foetal specimens from 48 fin whales, 17 sei whales and 2 humpback whales in the Antarctic. The foetal growth curve by Laws (1959)

is applied in this paper to obtain the accurate foetal month for the examined specimens. Through the naked eye observation during dissecting the external auditory meatus from the blind section to the glove-finger and through the histological examination on the celloidin section of the glove-finger, my findings are summarized as follows.

1. The shape of prenatal ear plug is determined by the difference in growth between the external auditory meatus and the glove-finger in the foetal stage of baleen whale. With regard to shapes, there are individual variations in the same species as well as the specific differences among baleen whales.

2. The prenatal ear plug is essentially maintained throughout the life span of the baleen whale. It is observed clearly in the ear plugs from the adult blue, fin, Bryde's and humpback whales but rarely in the ear plugs from adult sei and minke whales. In the sei and minke whale, the connection between the ear plug-core and the outer-covering is so weak that the ear plug is separated at the distal portion of the core in the course of removing ear plugs from the whale bodies. This implies some difficulties in age determination by ear plug for these two species.

3. The keratinization in the epidermal cells of the glove-finger appears at the 6 1/2 foetal month of the fin whale, according to the histological examination. It arises at the 8 1/2 foetal month of the sei whale. The observation by the naked eye for fetuses endorses this finding. The keratinized layer in the prenatal stage, showing great individual variation of thickness, remains as the first dark layer at the distal end of the plug-core.

4. The fatty degeneration in the epidermal cells of the glove-finger occurs at the 8th foetal months and continues to progress until birth in the fin whale. It also appears at the late foetal month of the sei whale. In the adult ear plugs from baleen whales, the fatty layer remains as the first bright layer following the above keratinized layer.

5. The neonatal line of the ear plug is defined as the part where the first bright layer ceases to grow.

6. The longitudinal bright layer is not yet present in the foetal ear plug.

7. The substances stimulating the foetal epidermis of the glove-finger to the fatty degeneration seem to be supplied through the maternal blood. The endocrine factors may act an important part.

REFERENCES

- Chittleborough, R. G. (1959). Determination of age in the humpback whale, *Megaptera nodosa* (Bonnaterre). *Aust. J. Mar. Freshw. Res.*, 10: 125-143.
- Crisp, D. T. (1963). The effect of whale length and post-mortem time on ease of removing ear plugs from fin whales. *Norsk Hvalfangst-Tid.*, 5: 121-123.
- Eschricht, D. F., & J. Reinhardt (1866). On the greenland right whale. Recent memoirs on the Cetacea. Roy. Soc. of London.
- Ichihara, T. (1959). Formation mechanism of ear plug in baleen whales in relation to glove-finger. *Sci. Rept. Whales Res. Inst.*, 14: 107-135.
- (1963). Photometric method for counting laminae in ear pug of baleen whale. *Sci. Rept. Whales Res. Inst.*, 17: 37-48.

- Laws, R. M. & P.E. Purves (1956) The ear plug of the Mysticeti as an indication of age with special reference to the North Atlantic fin whale (*Balaenoptera physalus* Linn.) *Norsk Hvalfangst-Tid.*, 8 : 413-35.
- Laws, R. M. (1959). The foetal growth rates of whales with special reference to the fin whale, *Balaenoptera physalus* Linn. *Discovery Repts.*, 29 : 281-308.
- Mackintosh, N. A. & J. F. G. Wheeler (1929). Southern blue and fin whales. *Discovery Repts.*, 1 : 257-540.
- Matthews, L. H. (1938). The sei whale, *Balaenoptera borealis*. *Discovery Repts.*, 17 : 183-290.
- Montagna W. (1962). *The structure and function of skin*. Academic press, New York. : 1-454.
- Nishiwaki, M., T. Ichihara & S. Ohsumi (1959). Age studies of fin whale based on ear plug. *Sci. Rept. Whales Res. Inst.*, 13 : 155-169.
- Ohsumi, S. (1960). Relative growth of the fin whale, *Balaenoptera physalus* (Linn.) *Sci. Rept. Whales Res. Inst.*, 15 : 17-84.
- Purves, P. E. (1955). The wax plug in the external auditory meatus of the Mysticeti. *Discovery Repts.*, 27 : 293-302.
- Purves, P. E., & M. D. Mountford (1959). Ear plug laminations in relation to the age composition of a population of fin whales (*Balaenoptera physalus*). *Bull. Brit. Mus., (Nat. His). Zool.*, 5 : 125-61.
- Rothman, S. (1954). *Physiology and biochemistry of the skin*. The University of Chicago press. Chicago ; 1-741.
- RUUD, J. T. (1940). The surface structure of the baleen plates as a possible clue to age in whales. *Hvalrådets Skrifter.*, 23 : 1-23.
- TULLBERG, T. (1883). Bau und Entwicklung der Barten bei *Balaenoptera sibbaldii*, *Nova Acta Soc. Sci. Upsal.*, ser. III, 11 : 1-36.

APPENDIX. THE BIOLOGICAL DATA FOR EXAMINED FOETUSES

FIN WHALE

No.	Date obtained	Foetal length in cm	Foetal month	Sex in foetus	Elapsed time after killing	No. of ovulation in mother's ovaries	Position captured
1	9, Jan. 1960	6.6	3/4-1	F	9-20	11	56°-19'S, 94°-56'E
2	4, Jan. 1960	19.0	1-3/4	F	12-40	25	57°-07'S, 100°-23'E
3	6, Jan. 1960	47.5	2 3/4-3	F	11-10	25	56°-34'S, 95°-09'E
4	26, Jan. 1960	52	3	M	7-10	7	60°-55'S, 153°-01'E
5	7, Jan. 1960	71	3 3/4-4	M	5-15	13	56°-26'S, 92°-57'E
6	29, Dec. 1959	79	4 1/4	F	7-40	2	58°-36'S, 92°-27'E
7	29, Jan. 1960	117	5 1/4	F	8-25	4	59°-31'S, 150°-14'E
8	28, Dec. 1959	122	5 3/4-6	M	6-20	14	59°-12'S, 94°-24'E
9	8, Jan. 1960	122	5 3/4-6	M	11-35	5	57°-00'S, 93°-36'E
10	30, Dec. 1959	127	6	F	2-55	9	57°-54'S, 93°-45'E
11	2, Feb. 1960	130	6-6 1/4	M	7-50	1	59°-32'S, 150°-47'E
12	23, Jan. 1960	140	6 1/4-6 2/4	F	6-50	22	62°-21'S, 146°-12'E
13	24, Jan. 1960	145	6 2/4	F	8-15	13	61°-43'S, 150°-17'E
14	30, Jan. 1960	145	6 2/4	F	12-15	11	59°-14'S, 148°-44'E
15	9, Mar. 1960	145	6 2/4	M	5-00	7	60°-54'S, 150°-57'E
16	10, Jan. 1960	165	6 3/4-7	M	11-40	7	56°-16'S, 92°-19'E
17	12, Feb. 1960	173	7	M	11-00	1	68°-24'S, 168°-12'W
18	31, Jan. 1960	175	7-7 1/4	M	6-15	2	60°-48'S, 148°-52'E
19	2, Feb. 1960	175	7-7 1/4	F	1-35	5	59°-32'S, 150°-47'E
20	11, Jan. 1960	183	7 1/4	M	9-35	3	57°-19'S, 91°-29'E
21	21, Jan. 1960	183	7 1/4	F	7-45	3	63°-16'S, 140°-23'E
22	22, Jan. 1960	183	7 1/4	F	12-45	2	62°-12'S, 144°-06'E
23	19, Jan. 1960	191	7 1/4-7 2/4	F	10-10	21	64°-06'S, 126°-32'E
24	28, Dec. 1959	203	7 2/4	M	5-25	19	59°-12'S, 94°-24'E
25	30, Jan. 1960	206	7 2/4-7 3/4	M	10-50	2	59°-14'S, 148°-44'E
26	29, Dec. 1959	219	7 3/4	M	5-50	14	58°-37'S, 92°-26'E
27	21, Jan. 1960	242	8-8 1/4	F	7-05	19	63°-16'S, 140°-23'E
28	30, Jan. 1960	252	8 1/4	F	10-30	2	59°-14'S, 148°-44'E
29	4, Jan. 1960	259	8 1/4	F	4-15	13	57°-07'S, 100°-23'E
30	4, Feb. 1960	264	8 1/4-8 2/4	F	4-55	9	59°-48'S, 150°-24'E
31	25, Jan. 1960	269	8 2/4	M	10-05	2	60°-38'S, 153°-56'E
32	30, Dec. 1959	280	8 2/4-8 3/4	M	3-25	12	57°-54'S, 93°-45'E
33	23, Jan. 1960	280	8 2/4-8 3/4	F	5-55	12	62°-21'S, 146°-12'E
34	4, Feb. 1960	292	8 3/4	M	6-05	13	59°-48'S, 150°-24'E
35	12, Jan. 1960	300	8 3/4	F	7-30	27	57°-00'S, 92°-57'E
36	18, Jan. 1960	300	8 3/4	M	11-55	16	64°-19'S, 122°-10'E
37	28, Dec. 1959	323	9	M	3-15	19	59°-12'S, 94°-24'E
38	28, Jan. 1960	338	9 1/4	F	5-55	15	60°-35'S, 150°-36'E
39	29, Jan. 1960	348	9 1/4	M	10-00	17	59°-31'S, 150°-14'E
40	29, Jan. 1960	353	9 1/4-9 2/4	F	12-50	20	59°-31'S, 150°-14'E
41	1, Mar. 1960	353	9 1/4-9 2/4	M	10-20	9	65°-05'S, 171°-48'E
42	25, Jan. 1960	374	9 2/4	F	5-00	10	60°-38'S, 153°-56'E
43	4, Feb. 1960	384	9 2/4-9 3/4	F	5-55	13	59°-48'S, 150°-24'E
44	9, Mar. 1960	424	10	M	13-35	4	60°-54'S, 150°-57'E
45	9, Mar. 1960	437	10	F	8-55	7	60°-54'S, 150°-57'E
46	22, Mar. 1960	440	10-10 1/4	F	1-25	4	59°-31'S, 150°-40'E
47	11, Mar. 1960	531	10 2/4-10 3/4	M	2-20	29	59°-31'S, 150°-35'E
48	22, Mar. 1960	556	10 3/4-11	F	2-05	17	59°-31'S, 150°-40'E

M: Male F: Female

SEI WHALE

No.	Date obtained	Foetal length in cm	Foetal month	Sex in foetus	Elapsed time after killing	No. of ovulation in mother's ovaries	Position captured
1	25, Jan. 1960	84	5-5 1/4	M	9-40	8	60°-38'S, 153°-56'E
2	12, Feb. 1960	153	7 1/4-7 2/4	F	5-25	4	68°-24'S, 168°-12'W
3	7, Feb. 1960	175	8 1/4-8 2/4	M	3-30	4	65°-10'S, 165°-00'E
4	29, Jan. 1960	183	8 2/4	M	8-30	10	59°-31'S, 150°-14'E
5	5, Feb. 1960	193	8 2/4	M	6-05	13	60°-29'S, 153°-46'E
6	7, Feb. 1960	198	8 3/4	M	3-40	8	65°-10'S, 165°-00'E
7	13, Feb. 1960	198	8 3/4	M	5-50	11	69°-01'S, 166°-11'W
8	25, Jan. 1960	242	9 1/4-9 2/4	F	9-00	6	60°-38'S, 153°-56'E
9	27, Jan. 1960	247	9 2/4	F	7-15	13	60°-19'S, 148°-42'E
10	2, Feb. 1960	249	9 2/4	M	9-05	6	59°-32'S, 150°-47'E
11	8, Feb. 1960	264	9 3/4	F	2-45	4	66°-53'S, 169°-22'E
12	12, Feb. 1960	300	10 1/4-10 2/4	M	8-05	6	68°-24'S, 168°-12'W
13	27, Feb. 1960	305	10 1/4-10 2/4	M	0-45	5	66°-43'S, 178°-54'W
14	8, Feb. 1960	315	10 2/4	F	3-50	9	66°-53'S, 169°-22'E
15	22, Feb. 1960	315	10 2/4	M	3-50	10	65°-32'S, 163°-04'W
16	10, Feb. 1960	323	10 2/4-10 3/4	M	4-45	13	69°-31'S, 179°-00'W
17	30, Jan. 1960	325	10 2/4-10 3/4	F	9-35	5	59°-14'S, 148°-44'E

HUMPBACK WHALE

No.	Date obtained	Foetal length in cm	Foetal month	Sex in foetus	Elapsed time after killing	No. of ovulation in mother's ovaries	Position captured
1	21, Jan. 1960	109	6 1/2	M	3-45	8	63°-16'S, 140°-23'E
2	21, Jan. 1960	125	6 3/4	M	7-05	8	63°-16'S, 140°-23'E

M: Male F: Female

EXPLANATION OF PLATES

PLATE I

Fig. 1. The cross section of the glove-finger from the 3 3/4-4th foetal months of the fin whale ($\times 400$). The compact basal layer, covered by periderm cells, some of which are exfoliating. The basal layer is composed of low cuboidal cells.

P: Periderm
BL: Basal layer
CT: Connective tissue

Fig. 2. The cross section of the glove-finger from the 8 1/2-8 3/4 foetal months of the fin whale ($\times 100$). The thick epidermis is much proliferated. The keratinized layer is disconnected from this specimen.

BL: Basal layer
CT: Connective tissue

PLATE II

Fig. 1. The cross section of the glove-finger from the 9 1/4-9 1/2 foetal months of the fin whale ($\times 100$). The keratinized layer darkly stained by eosin, is clearly found at the most outer side of the epidermis. The most part of keratinized layer is disconnected from this specimen.

KDS: Keratinization darkly stained by eosin

BL: Basal layer

Fig. 2. The enlarged photomicrograph for the same specimen ($\times 300$). The lipid granules are found in the cytoplasm of the upper prickle-cell layer. There are many transformed nuclei.

FC: Fatty degenerated cell

PLATE III

Fig. 1. The cross section of the glove-finger from the 10th foetal months of the fin whale ($\times 100$). The fatty degenerated layer is clearly observed. The most part of keratinized layer is disconnected from this specimen.

KDS: Keratinization darkly stained by eosin

BL: Basal layer

Fig. 2. The enlarged photomicrograph for the same specimen ($\times 400$). Swelled cells, undergoing the fatty degeneration, are found at the upper prickle-cell layer. At the most outside of the fatty layer depressed nuclei remain yet. The keratinized layer darkly stained by eosin is found at the most distal end.

FC: Fatty degenerated cell.

FL: Fatty layer.

PLATE IV

Fig. 1. The epidermis from the 10 3/4-11th foetal months of the fin whale ($\times 100$). The lower parts of keratinized layer is on the thick fatty layer.

KL: Keratinized layer

FC: Fatty degenerated cell

Fig. 2. The enlarged photomicrograph for the same specimen indicates the fatty degenerated cells at the prickle-cell layer ($\times 400$). The keratinized cell is about the same size as the fatty degenerated cell.

KC: Keratinized cell

FC: Fatty degenerated cell.

PLATE V

The prenatal layers remaining at the most distal ends of plug-cores from adult baleen whales. Prenatal layers are composed to two layers: keratinized (KL) and fatty degenerated (FL) layers.

Fig. 1. Fin whale ear plug

2. Blue whale ear plug

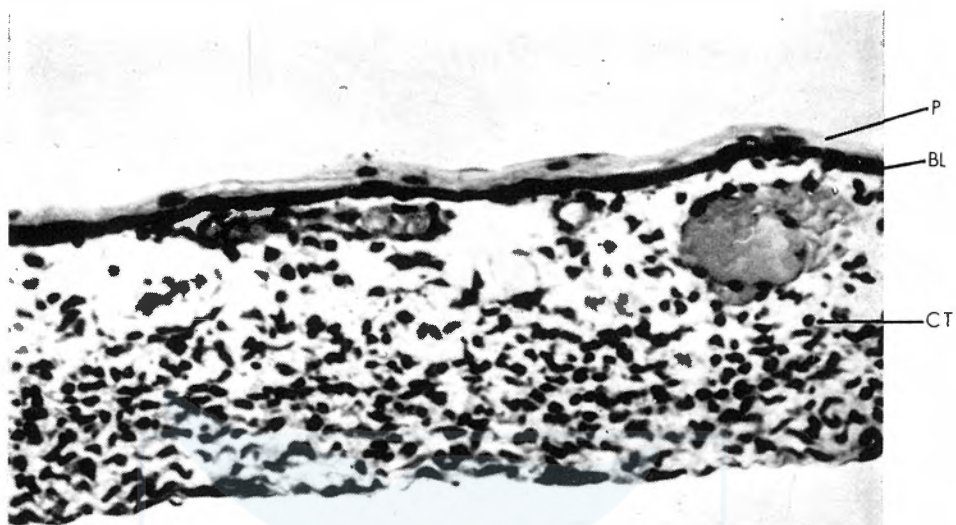
3. Humpback whale ear plug

4. Sei whale ear plug

5. Bryde's whale ear plug

PKL: Keratinized layer of the prenatal stage

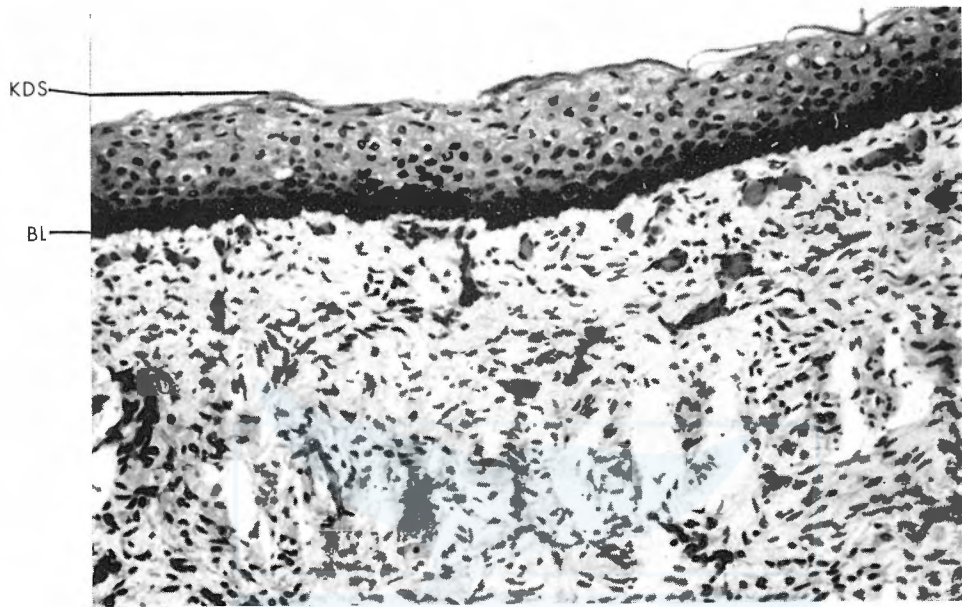PFL: Fatty layer of the prenatal stage




1



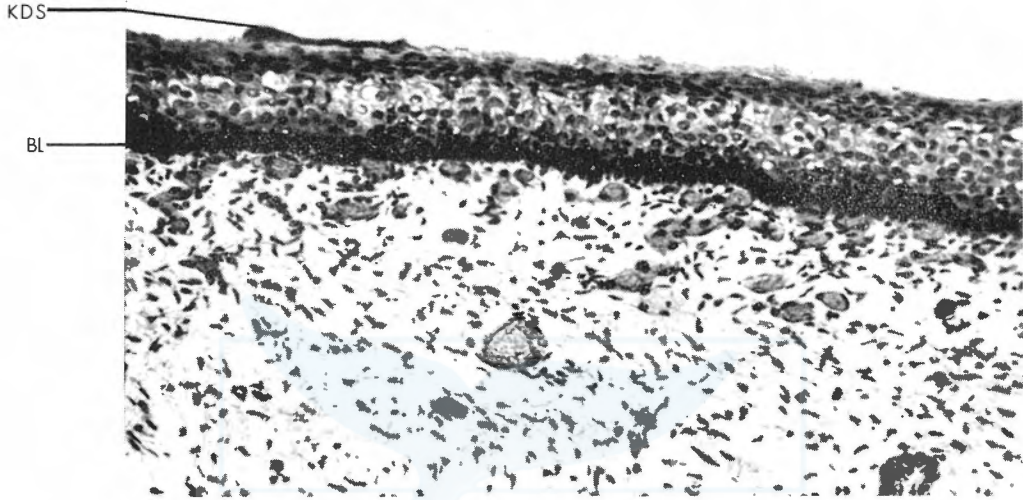
2



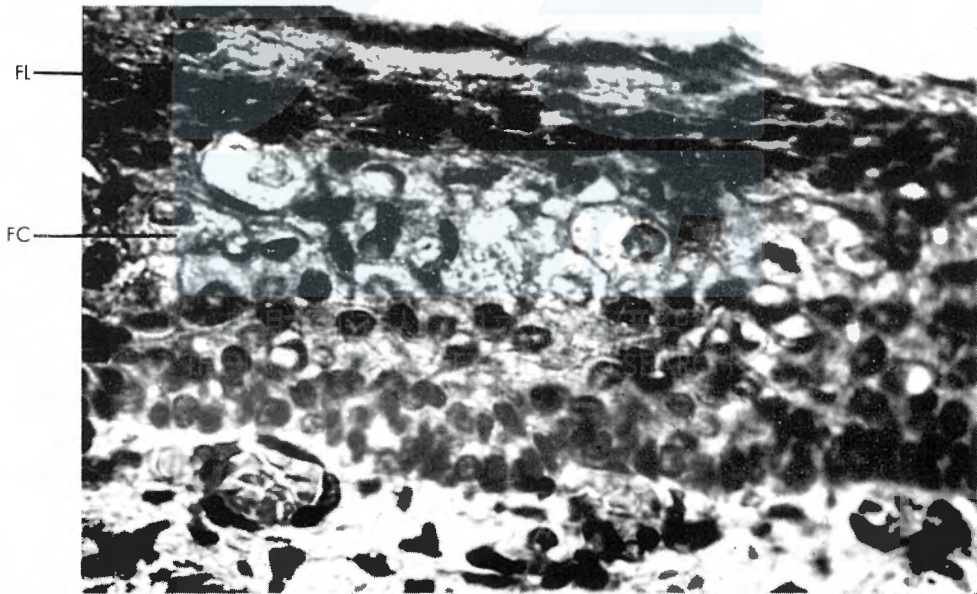
1



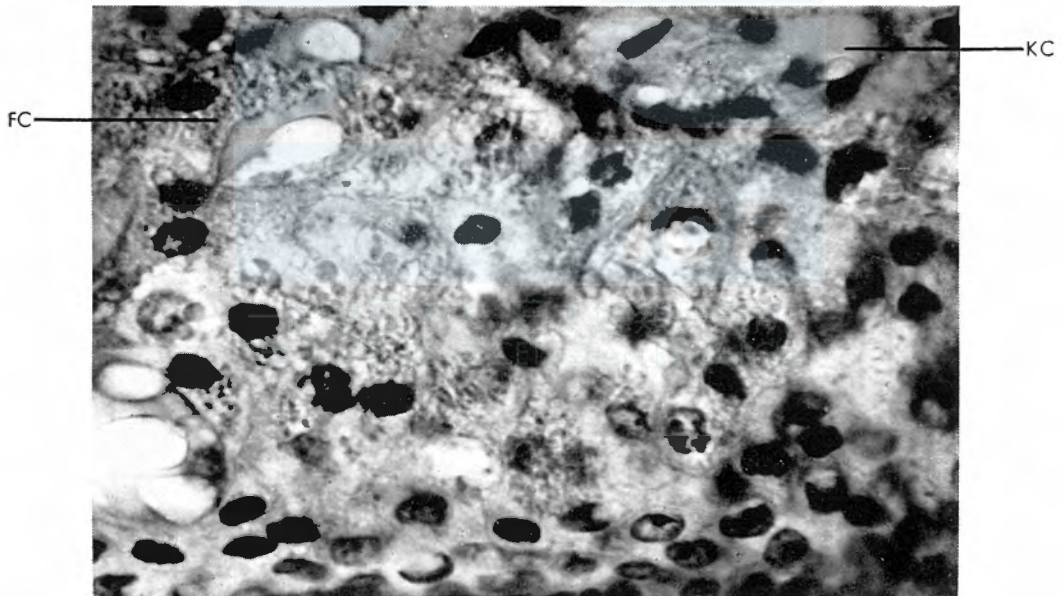
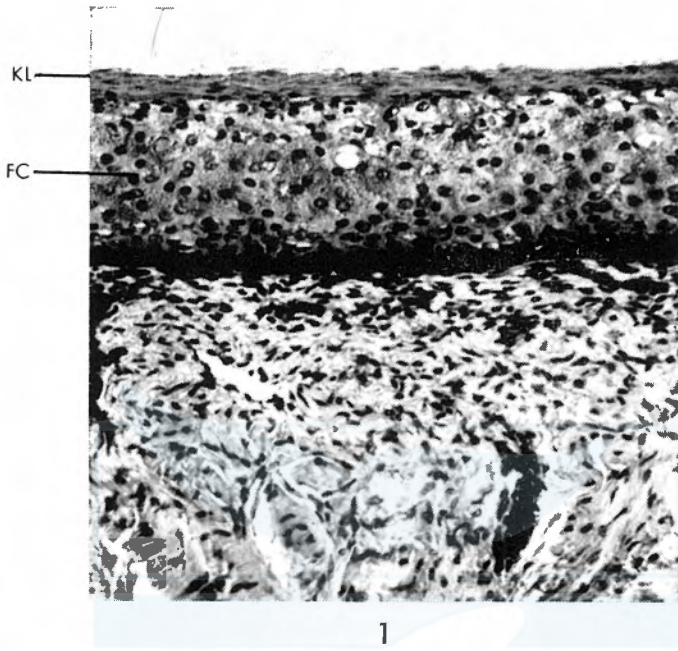
2



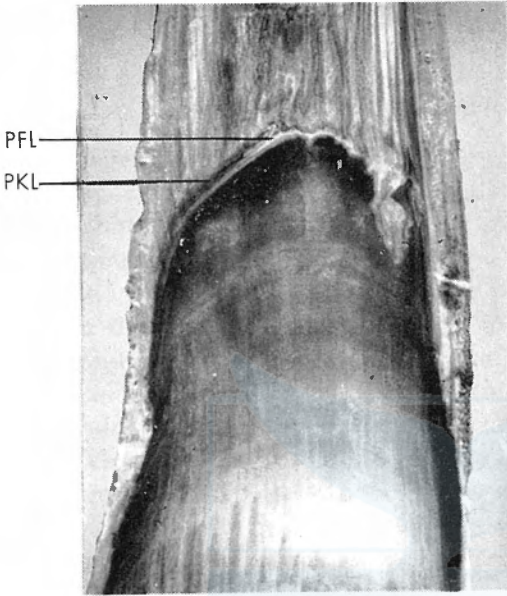
1



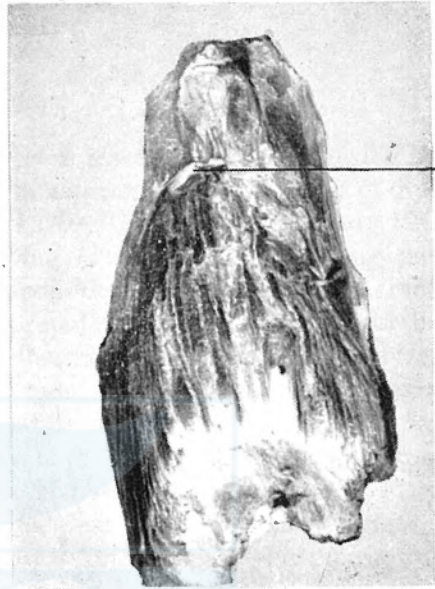2



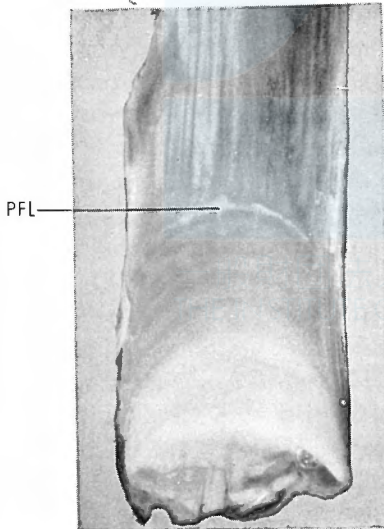
2



1



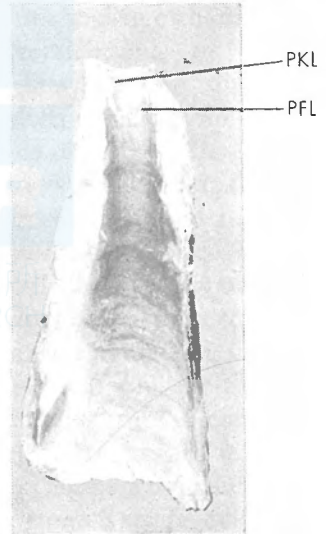
2



3



4



5