

White Scars on Whales

(I) Lamprey Marks

By

TAKAHISA NEMOTO

The so-called white scars on the skin of whales have been reported on various species of whales and from various whaling grounds in the world. The cause of the formation of these scars has remained long in doubt. *Coronula*, *Pennella*, sucking fish or sharp rocks were suggested as probable causes in the early days, however, Mackintosh and Wheeler (1929) describe that it does not seem possible to explain the various stage of the scar by any of such theories and the balance of probability indicates that they are primarily the work of micro-organisms, the ciliated protozoa. But recently Pike (1951, 1953) reports that these oval white scars on whale were attributable to the attacks of parasitic lampreys and the open pits in the blubber of whales were interpreted as healing stages which succeeded the lamprey attacks. He also considers it is probable that ciliated protozoa aggravated those wounds by invading the previously punctured skin.

I had studied these lamprey marks on whales processed on the Japanese whaling factory ship "Baikal-Maru," which operated in the Northwestern part of the Northern Pacific in 1953 and from whales processed at various landstations in Japan in 1954, including those taken in the Okhotsk Sea. After having studied, I get to a conclusion that the marks caused by the attacks of the lamprey are identified from those reported by various authors previously as white scars, the details of which are reported in this paper.

I am much indebted to Dr. H. Omura, the president of the Whales Research Institute, who kindly read the draft of the manuscript and criticized it and to Mr. K. Fujino, a research member of the said institute for the precious suggestions. My sincere thanks are due to Dr. H. Yabe of the Nankai Regional Fisheries Laboratory, to whom I am indebted for the splendid photographs shown in Fig. 10. The crew of the whaling factory ship "Baikal-Maru" and the staffs of the landstations immensely aided me in the observations in the field. To all, I also extend my sincere thanks.

According to my observation, the same species of sea lamprey as reported by Pike (1951) attacks whales also in the western part of the Northern Pacific. This Pacific sea lamprey, *Entosphenus tridentatus* distributes in the broad region from the Arctic as far south as southern

California in the American side and down to about 35°N Latitude in the

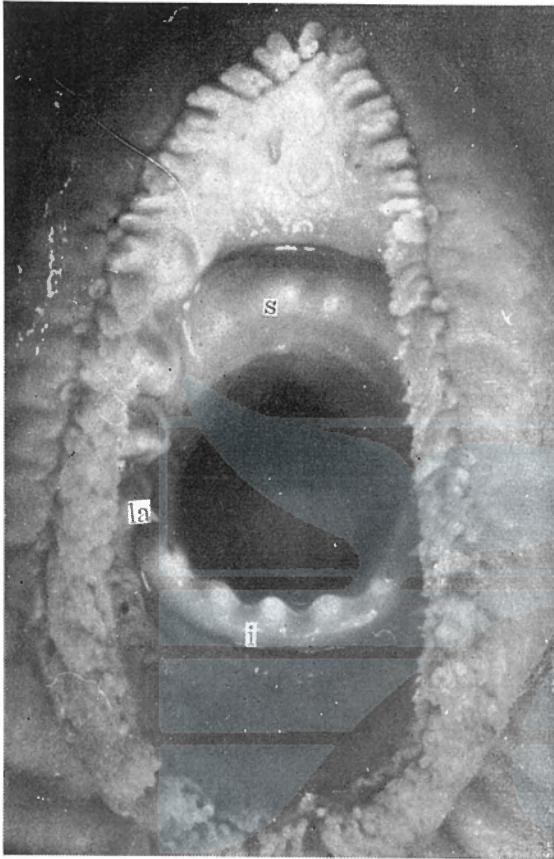


Fig. 1. Sucking disk of Pacific sea lamprey. ($\times 4$)

- s) supraoral lamina.
- i) infraoral lamina.
- la) lateral teeth.

A typical lamprey mark is shown in Fig.2. This mark coincides closely with the structure of the sucking disk of the lamprey. It is thought that the lamprey sticks to the whale skin with its sharp teeth and cusps at first and then bite the epidermis of the whale with its lingual lamina, when it attacks

western side of the Northern Pacific. It is well known that this species attack also fish, e.g. salmon or cod, causing a great harm to the fishery, especially in the American side. Like the Japanese river lamprey (*Lamptera japonica*) its dorsal fin is separated into two regions, however, the species is identified by having three acute cusps in the supraoral lamina from the Japanese river lamprey.

The infraoral lamina has five sharp cusps. Amidst of the mouth there is lingual lamina in which many small denticles are present, and on both sides of the sucking disk there present four series of lateral teeth, usually consisted of the arrangement of the teeth of 2-3-3-2 (Fig. 1).

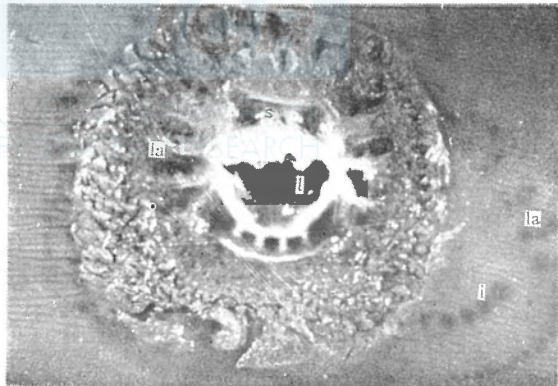


Fig. 2. Fresh mark of lamprey on a fin whale. ($\times 1$)

- s) marks caused by the supraoral lamina.
- l) hole by the lingual lamina.
- la) marks by the lateral teeth.
- i) marks by the infraoral lamina.

whale. The marks caused by such teeth are always left on the skin of the whale, even the lamprey shifted its sucking place to another by some reasons. In Fig. 2, there shown also some marks caused by the lateral teeth and by the infraoral lamina, outside the typical mark of lamprey's sucking disk. In the course of the sucking, the epidermis of the whale is abraded and also the blubber itself is rasped off, leaving there a round or oval open pit of about one centimeter deep. The skin around this pit is sometime injured by the suckers, showing a spongy appearance (Fig. 3).

Various healing processes are observed according to the degree of the wounds caused by the lamprey's attack. In most popular case, the spongy portion of the skin turns into blownish in color and becomes very fragil in structure and finally replaced by the regenerated skin of decreased amount of pigmentation (Fig. 4).

However, in case of the blubber is scooped off deeply, the blubber fibres grow up and draw

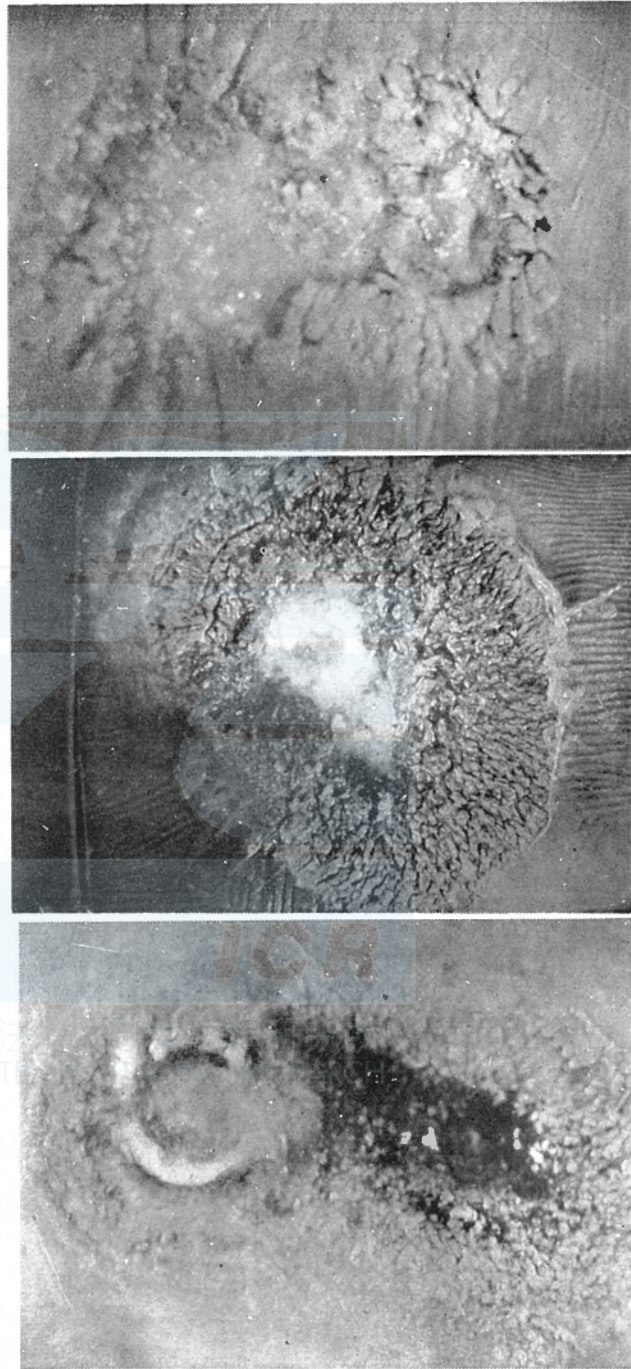


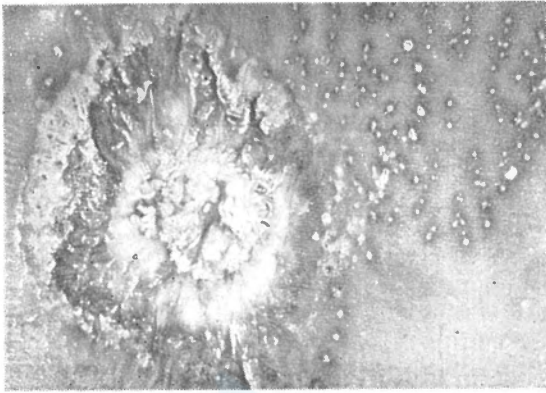
Fig. 3. Various types of irregular wounds by lamprey attacks on fin whales. ($\times 2$)

together causing a progressive closing of the pit, as reported by Pike (1951) (Fig.5). Such cases were observed only in very few occasions in the 1953 operation in the Northern Pacific.

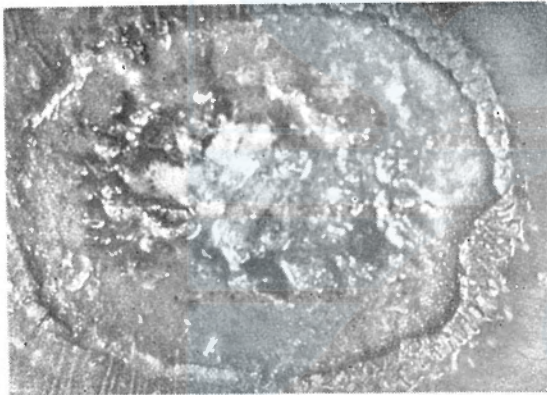
There are some occasions in which the lampreys shifting their positions without losing hold, leaving there two types of wounds.

One type is reported by Pike (1951) as "during this process the teeth make parallel incisions in the epidermis as long as eight or nine feet". These incisions are noticed usually as black lines on the epidermis and mostly ending as a usual sucking mark (Fig. 6). Another type is shown in Fig. 7 (a), in which the lamprey shifts its position as long as 10 centimeters in the progress of the sucking, continuing the abrasion of the skin.

Unlikely to the former case, not only lateral teeth, but also lingual laminae are used for biting in this



(a)



(b)

Fig. 4. Half healed scars on fin Whales. ($\times 2$)

- (a) Notice the metamorphosis of spongy section in the hole.
 (b) Notice the recovery of the black epidermis about the hole caused by lingual lamina.

case, leaving there oval, horse-shoe-shaped, or belt-like white scars, usually running along the axis of the body and about 0.5 centimeters deep (Figs. 7, 8, 9). Also in this type of scars some marks of the lateral teeth are usually left on the skin (Fig. 7(b)).

These lamprey marks are identified from the so-called white scars, reported previously by various authors from the different part of the ocean, in the following three points:

(1) Although in almost all lamprey marks the teeth marks are present, but in the so-called white scars reported from southern hemisphere by Mackintosh and Wheeler (1929) or from the Bonin waters

by Omura (1950) no tooth mark is noted. Even the open pits on the whales from these waters bear no sign of teeth.

(2) Various shapes of scars are observed in the lamprey marks, e.g. round, oval, horse-shoe-shaped, or belt-like. However, in the so-called white scars its shape is generally oval.

(3) The open pits caused by the attack of the lampreys are more shallower than those reported from Saldanha Bay by Mackintosh and Wheeler (1929) and Matthews (1938) or from Bonin Island by Omura (1950). Accordingly, the former scars are identified from the latter

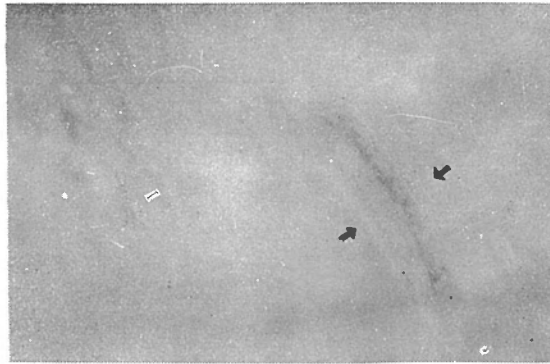


Fig. 5. Half healed lamprey scar on the white portion of a fin whale. ($\times 1$)

Notice, blubber fibers grow up from the both side of the scar.

1) lateral teeth marks caused by incomplete attacks.



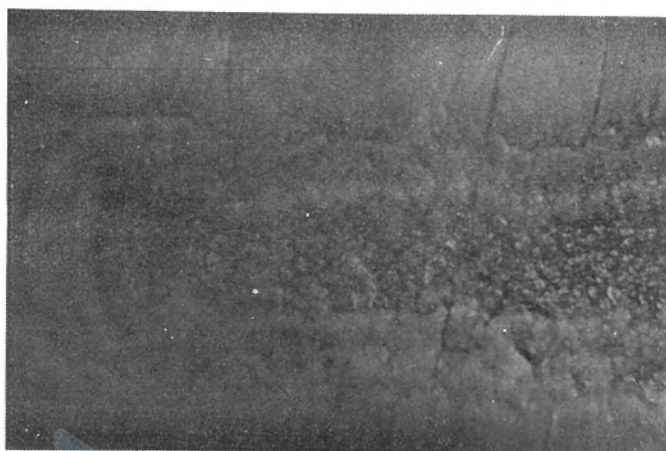
Fig. 6. Typical white scars on a sei whale by the lamprey attack. ($\times 1$)

Healed white scar showing the sucking scar (w) and the changing of lateral teeth (1). Notice the lamprey scar (w) definitely differ from the so called white scar on whales.

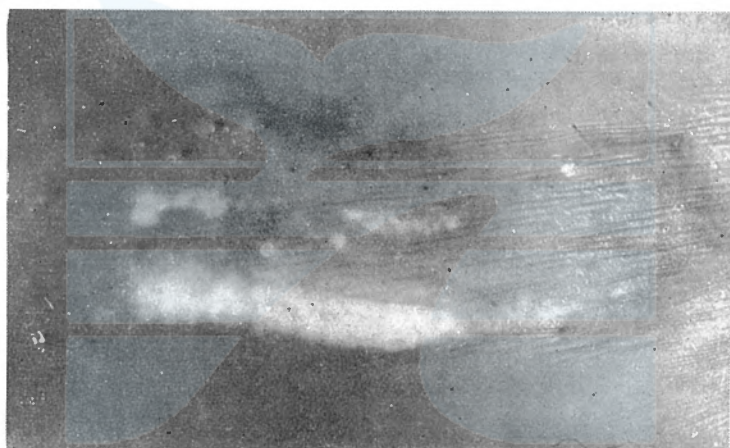
even after healed, by having a shallower mass of converging fibres in the blubber in sections.

Furthermore, the open pits of the so-called white scars are seen most frequently in the Bonin waters than any other waters adjacent to Japan as reported by Omura (1950). If the causes of the white scars are attributable solely to the attack of the sea lampreys as stated by Pike (1951), more open pits should be observed from the northern part in

the adjacent waters of Japan, judged from the abundance and the distribution of this kind of fish, though details of which are left in future investigations. Quite recently, Dr. H. Yabe kindly forwarded me some photographs of open pits on the skin of the yellow-fin tuna shown in Fig. 10. These open pits resemble very closely to those found on the skin of whales from the Bonin waters and no teeth mark is left on



(a)



(b)



(c)

Fig. 7. Belt-like scars on fin whales. ($\times 1$)
Notice the marks by lateral teeth on a healed scar (b).

the surface of the body. The skin and meat is scooped out very deeply in these two fish, one pit near the operculum being reached to the abdominal neal cavity. These yellow-fin tuna (*Neothunnus macropterus*) were caught in the Timor Sea, Indian Ocean at a point 9°39'S. Latitude and 122°19'E. Longitude, by the long line on 12th January 1953. One of these fish was 125 centimeters in length, measured in fork length. Another fish was not measured of its length, but was reported as nearly the same length.

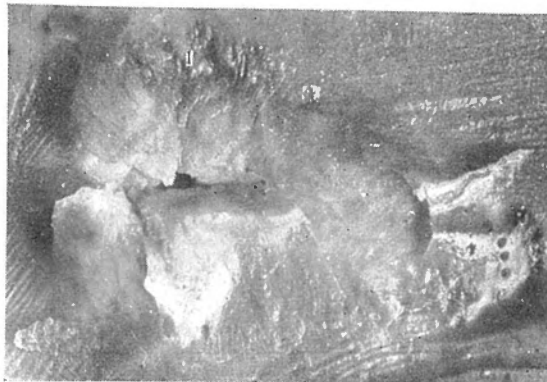


Fig. 8. Horse-shoe-shaped lamprey scar. ($\times 1$)
Notice the teeth marks about lamprey scar.
1) lateral teeth marks.




Fig. 9. Healed scar by slight lamprey attacks. ($\times 1$)

According to Dr. Yabe, these open pits or healed scars of these pits are observed on the body of the fish in these waters rather frequently. It is clear that these open pits can not be attributable to the attack of the sea lamprey. Pike (1951) describes that lamprey may constitute the universal cause for the scars, but it seems to me unlikely. My opinion is that the lamprey constitutes one cause for the scars and another causes are left still in doubt. The crescent-shaped scars were considered as the result of the insecure attachment of the lamprey by Pike (1951), however, I could not conclude so, because it

is hardly suggested from Figs. 7 and 8 of the Pike's report. The teeth marks shown in Fig. 7 are not deemed as a cause of the cres-

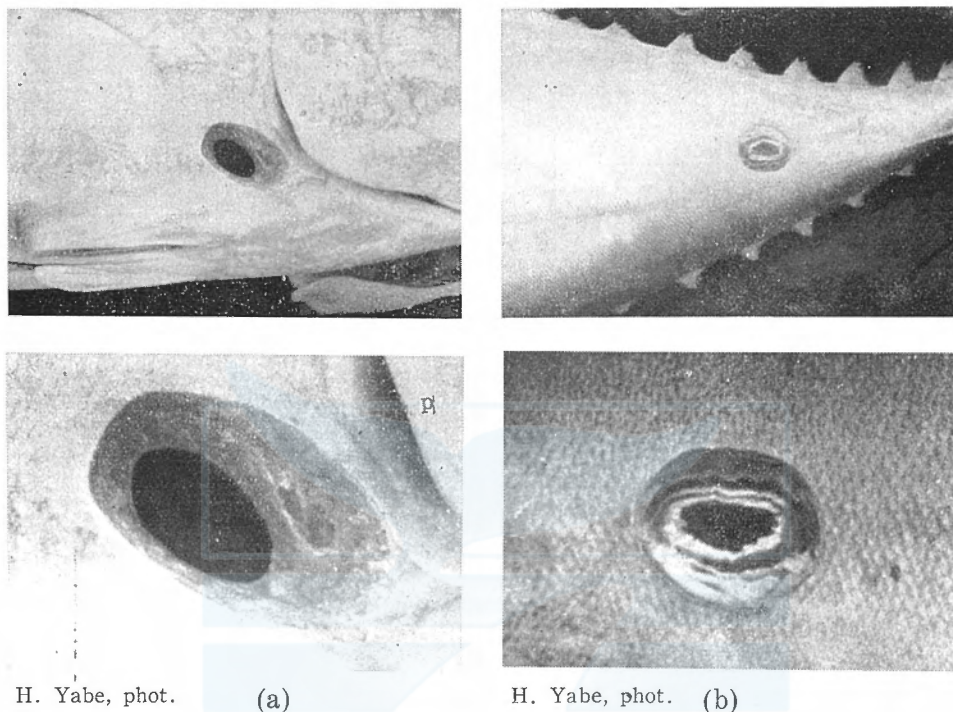


Fig. 10. Open pits on yellow-fins from the Timor Sea.
 (a) pit penetrated into the abdominal neal cavity near the operculum.
 p) operculum of yellow fin.

cent-shaped scars shown in Fig. 8, though the both shapes resemble very closely. Also the white scar shown in Fig. 4 in his report is thought as a healing stage of the open pit by unknown cause. It is reasonable to conclude that the scar shown in Fig. 3 in the same report is caused by the attacks of a lamprey, but it is thought to me to be incorrect that the white scar of Fig. 4 be attributed to the lamprey's attack, bearing no tooth mark around it.

According to my observation, the so-called white scars remain on the skin of the whales for several years as reported by various authors, but the lamprey marks does not last so long and become very difficult to identify after an interval of about one year, except those caused by heavy attacks.

In conclusion, one cause of the white scars on the skin of the whales should be attributed to the attack of the sea lamprey, but another causes are left still in the future investigations.

Literature

- Andrews, R. C., 1916: The Sei Whale (*Balaenoptera borealis* Lesson). Memoirs of the American Museum of Natural History.
- Hatta, S., 1915: The review of lamprey. Japan Journal of Zoology, Vol. 27, pp. 324-325.
- Mackintosh, N. A, and Wheeler, J.F.G., 1929: Southern Blue and Fin Whales. Discovery Reports, Vol. 1, pp. 257-540.
- Matthews, L. H., 1938: The Humpback whale (*Megaptera nodosa*). Discovery Reports, Vol. XVII, pp. 7-92.
- Matthews, L. H., 1938: The Sei Whale (*Balaenoptera borealis*). Discovery Reports, Vol. XVII, pp. 183-290.
- Nozawa, Y., Takayama, I., and Nemoto, T., 1954: Biological Investigation of the Northern Pacific Baleen Whales caught by the Japanese Whaling Fleet in 1953. Fisheries Agency of Japanese Government.
- Okada, Y., and Matsubara, K., 1938: Keys to the Fishes and Fish-like Animals of Japan.
- Omura, H., 1950: Whales in the Adjacent Waters of Japan. Scientific Reports of the Whales Research Institute, No. 4, pp. 27-114.
- Omura, H., Nishimoto, S., and Fujino, K., 1952. Sei Whales (*Balaenoptera borealis*) in the Adjacent Waters of Japan. Fisheries Agency of Japanese Government.
- Pike, G. C., 1951: Lamprey Marks on Whales. Journal of Fisheries Research Board of Canada, Vol. VIII, No. 4, pp. 275-280.
- Pike, G. C., 1953: Progress Reports of Pacific Coast Stations, No. 97, pp. 3-5.



一般財団法人 日本鯨類研究所
THE INSTITUTE OF CETACEAN RESEARCH