

On the Cetacean Larynx, with Special Remarks on the Laryngeal Sack of the Sei Whale and the Aryteno-Epiglottideal Tube of the Sperm Whale

by

Hiroshi Hosokawa

Department of Anatomy (Professor Dr. T. Ogawa),
Medical School, University of Tokyo.

Introduction

Since very early the larynx of the whales has, because of its peculiar structure, attracted notice of many anatomists. The most striking peculiarities lies in the tube formed by the upward elongated epiglottic and arytenoid cartilages and dilated at its summit like a knob, protruding into the choana. After Tyson (1680), who observed this tube for the first time in *Phocaena communis*, a number of anatomists described this structure in various kinds of whales, for instance, J. Hunter (1787) in the harbour porpoise, dolphin, pottfisch and narwhal, Meckel (1833) in *Delphinus* and *Phocaena*, Stannius (1846) in *Delphinus* and *Monodon*, Vrolick (1848) in *Hyperoodon*, Huxley (cited from Howes), Burmeister (1867), Howes (1879), Rawitz (1900) and Boenninghaus (1902) in *Phocaena communis*, Murie (1871, 74) in *Grampus rissoanus* and *Globicephalus*, Watson and Young (1878—79) in *Beluga leucas*, Dubois (1886) in *Hyderoodon*, *Tursiops*, *Phocaena*, *Delphinus* and *Globicephalus*, and Benham (1901) in *Cogia breviceps*. To the last mentioned author we owe probably the name "arytenoepiglottideal tube".

Meanwhile it is worthy of notice that research materials of these anatomists were always toothed whales. The question naturally arises, whether the whalebone-whales have also the same tube in the larynx.

This problem was answered by Eugen Dubois (1886), who compared the larynges of *Hyperoodon*, *Tursiops*, *Phocaena*, *Delphinus* and *Globicephalus* with that of a fetus of *Balaenoptera Sibbaldii*, and asserted the non-existence of the aryteno-epiglottideal tube in the latter. Besides there are, according to him, many other differences in the larynx between whalebone and toothed whales.

While engaging recently in the anatomical research upon some whales,

I was much interested by the striking difference in the larynx between two groups of the whales and was led to make some detailed inquiries about this matter.

The following materials have been hitherto examined by me in this research. Whalebone whales:

1. *Balaenoptera borealis*, 42 feet, female; 46 feet, female (at Ayukawa, Miyagi Prefecture).
2. *Balaenoptera musculus*, fetuses of various lengths (in Antarctic Ocean).
3. *Balaenoptera physalus*, fetuses of various lengths (in Antarctic Ocean).

Toothed whales:

4. *Physeter catodon*, 32 feet, male; 36 feet, female (at Ayukawa).
5. *Lagenorhynchus obliquidens*, male fetus of 51 cm length (at Kawana, Shizuoka Prefecture).
6. *Prodelphinus caeruleo-albus*, 11 feet, male; 117 cm, female (at Kawana).
7. *Globicephalus melas*, 15 feet, male; 16 feet, female (at Ayukawa).

In this paper I will treat mainly the larynx of the Sei whale (*Balaenoptera borealis*) and that of the Sperm whale (*Physeter catodon*); observations on the larynges of the others will be reported later.

I. Cartilages of the larynx

The larynx of the whales is constructed, as in other mammals, of the cartilagenous framework and several muscles connecting the cartilages. They form as a whole a tubular organ with the laryngeal cavity in it. The inner surface is covered with the mucous membrane continuous with that of the pharynx upwards and of the trachea downwards.

The laryngeal cartilages are five in number, three of which (thyroid, cricoid, epiglottic) are unpaired and the rest two are paired (arytenoid). The corniculate and the cuneiform cartilages do not exist as separated ones. At first the form of each cartilage will be mentioned, compared between the Sei and the Sperm whale.

The THYROID cartilage

Sei whale: (fig. 1) Two laminae, right and left, of this cartilage are fused together in the anterior middle line, there forming no sharp angle.

The cartilage is as a whole a plate concave behind and shaped like a flying swallow, providing with four processes; the inferior cornu, corresponding to wings of the swallow, is very well developed, projects caudally and makes a joint with the cricoid. The upwards directed superior cornu is not so well developed. Between the superior horns of both sides a deep V-shaped notch exists, separating partly the right and the left lamina (*incisura thyroidea cranialis*). The caudal border has in the median line a shallow notch (*incisura thyroidea caudalis*).

The outer surface of the laminae, smooth and convex as a whole, shows no remarkable prominence. The thyrohyoid and sternothyroid muscles are attached to relatively small areas near the superior lateral border of the lamina. The cricoarytenoid muscle inserts partly to the outer surface around the caudal notch, but for the greater part to the inner surface of this cartilage. To the inner surface are attached also three muscles, thyropharyngicus, thyroarytaenoideus and thyroepigloticus. Moreover the posterior end of the inferior horn is connected with the musculus cerato-cricoarytaenoideus dorsalis.

Sperm whale: (fig. 1') The thyroid is the largest cartilage in the larynx of this whale, differing in shape very little from the homologous structure in most of other mammals. Two laminae, right and left, are fused together at the middle front, forming a tolerably sharp angle, and there we see the *prominentia laryngica*.

The superior horn is very slight, and the inferior one is also not so well developed as in the Sei whale. Each lamina is irregularly triangular in shape; its outer surface is not smooth, having along its upper border a lineal crest, which courses downward to the middle portion of the lamina, and is divided there in two crests; one of them goes to the dorsal side, slightly inclining to the caudal direction, while the other runs ventrocaudally, and serves as insertion for the thyrohyoid and sternothyroid muscles. At the point, where the lineal crest changes its course from the upper border to the middle of the lamina, it surrounds a pore, foramen thyroideum, through which a nerve (the inner branch of the *n. laryngicus cranialis*) and a vessel (*a. laryngica cranialis*) penetrate. Existence of such a pore was mentioned already by Stannius in various whales, and by Rawitz in *Phocaena communis*.

The inner surface of the lamina is nearly smooth and gives attachment

to the thyropharyngeal and thyroarytenoid muscles etc.

The EPIGLOTTIC cartilage

Sei whale : (fig. 2) This elastic cartilage is not so hard as other larygeal cartilages. Its upper half, not so dilated widely as in the human larynx, is concave behind and convex in front. The lower half (petiolus epiglottidis) is long and thin, and directed to the cranial notch of the thyroid cartilage.

Sperm whale : (fig. 2') This large cartilage is an elongated triangle in shape seen from lateral, with an apex directed ventro-cranially, where the hyo-epiglottic muscle is attached. The cranial apex is, seen from behind, triangular and involved forwards.

The hind surface of this cartilage has three lineal longitudinal elevations, one in the median line and two others along the lateral margins; the latter meet with the lateral border of the arytenoid cartilage and are connected with it by the mucous membrane, forming so together the aryteno-epiglottideal tube.

The caudal end of this cartilage has a tubercle, which is connected to the angle between two laminae of the thyroid cartilage, a little below the cranial notch. This connection is strengthened by solid ligamentous fibres.

The CRICOID cartilage

Seiwhale : (fig. 3) The name "cricoid" does not hold good for this whale, for the cricoid cartilage is not shaped like a signet-ring as in other mammals, but its ventral half, corresponding to arcus, is completely deficient and the whole cartilage is merely a plate concave in front. The upper margin of this plate has a slight prominence at the middle, and a little more laterad on each side an articular facet for the arytenoid cartilage.

Caudally it is directly united with the tracheal cartilages, forming together the cricotracheal plate in the dorsal wall of larynx and trachea. Lateral parts of this plate are partially separated by a longitudinal notch from the main medial portion and may be named "processus lateralis"; the inner concave surface of this lateral process gives attachment to a portion of muscles of the laryngeal sack, which will be mentioned later. Moreover, the m. cricothyroideus inserts to the outer surface of this process, a little above its caudal end.

Inner and outer surfaces of the cricoid cartilage, nearly smooth all over, have a slight crest along the median part of the outer surface, which runs from the upper border downwards, remarkably dilating. Wide areas on both sides of the crest are for insertion of the dorsal cricoarytenoid muscles. The most caudal part of this area is connected with the cricopharyngeal muscle. A little more mediad than the upper end of the notch, which demarcates the lateral process, there are articular facets for the inferior horns of the thyroid cartilage. This joint is not fully diarthrodial but somewhat syndesmodial, strengthened behind by fibrous bands, while the aryteno-cricoid joint is diarthrodial, provided with the articular capsule.

Sperm whale: (fig. 3') This whale has a completely ring-formed cricoid cartilage, a very different circumstance therefore from the Sei whale. This fact deserves special attention, for, according to Dubois, all of the toothed whales he examined, with the exception of Tursiops, have incompletely ring-formed cricoid cartilage; in them the ventral portion is said to have a fissure, though the fissure is not so broad as in whalebone whales. Sanctis (1879) seems to have found in *Physeter macrocephalus* the same matter as in *Tursiops* (cited from Dubois); and Benham found also in an adult male *Cogia* a completely ring-shaped cricoid cartilage. In other toothed whales examined by me the matter is quite the same as Dubois described. Therefore, as to the cricoid cartilage there are two groups in the toothed whales, one of which (*Physeteridae* etc.) has a completely ring-shaped cricoid cartilage, while the other (*Delphinidae* and *Hyperoodon*) an incomplete one. The cricoid cartilage of the sperm whale is not united with the tracheal cartilages, a distinct space filled with fibrous bands existing between them.

The very thick posterior portion of the cricoid cartilage gives attachment to the dorsal cricoarytenoid muscle, while the middle portion of its cranial border is connected with some fibres of the transverse arytenoid muscle. The anterior part of this cartilage is narrow and somewhat thin, but widens as it approaches the median line.

The ARYTENOID cartilages

Sei whale: (fig. 4) Each of the paired cartilages has two processes directed up and down (*processus cranialis* and *proc. caudalis*). The tongue-shaped cranial one is thin in the transverse direction, while the caudal one

is thick and rounded. The pointed ends of the caudal processes are connected by fibrous tissue between both sides. The main part of the cartilage, corpus, has a laterally directed large prominence, which corresponds probably to the processus muscularis, giving attachment for the dorsal cricoarytenoid muscle etc. The dorsal surface of this portion has an oblique oval facet to articulate with the upper border of the cricoid cartilage. The corpus has furthermore a crest along the medial border of its ventral surface, probably homologous to the processus vocalis. Upon the relation of various muscles to this cartilage I want to refer it to the accompanying figures.

Sperm whale: (fig. 4') The most remarkable difference upon the arytenoid cartilage between Sperm and Sei whale is the absence of caudal process in the former. In the Sperm whale the well developed cranial processes of both sides, standing side by side on the cricoid cartilage, form a concave furrow in front, and their upper ends are fused together into one cartilage. Between the ventrolateral border of this process and the lateral crest of the epiglottic cartilage a fold of mucous membrane (plica aryepiglottica) is stretched and thus the aryteno-epiglottideal tube is completed.

The CORNICULATE and the CUNEIFORM cartilages

These cartilages could not be found in all the whales I have examined, at least as separated ones. Almost all of the authors who have studied the larynx of whales did not mention about them. Watson and Young denied the existence of them in Beluga. But Howes remarked in a fetus of *Phocaena* that the arytenoid cartilage consists of two separated pieces, and the upper portion of the so-called arytenoid, which is prolonged into the nasal passage, must represent an elongated cuneiform cartilage, the Santorinian element being absent. Negus (1928) agreed with Howes; he had examined a reconstruction model of the larynx of a fetal Sperm whale, which was 4.5 inches long, and finding two columns of mesenchymal, cartilaginous cells lying above and slightly ventral to the arytenoids, mentioned confidently that these cell-groups would make the cartilages of Wrisberg and, together with the epiglottis, constitute the peculiar laryngeal tube. Of the Santorinian cartilage he denied its existence. In small fetuses of Blue and Fin whales I examined minutely the cranial process of the arytenoid, but no separated piece of the cartilage was found, and in a

very small fetus (17 cm of length) of *Megaptera nodosa*, I saw that only the corpus of the arytenoid consists of cartilaginous element, the cranial process being formed merely of connective tissue.

The TRACHEAL cartilages

As these are closely related to the larynx, I will give a brief description of them.

Sei whale: (fig. 3) All of the tracheal cartilages are continuous with each other and moreover, as mentioned above, with the cricoid cartilage in their dorsal parts, forming altogether a single plate. In the lateral parts they are however separated from each other by transverse fissures and the ventral portions are completely wanting. Though Dubois stated that only the upper 4—5 tracheal cartilages are fused with the cricoid in a fetus, of *B. Sibbaldii*, in my observation of the Sei whale all of the eight cartilages up to the bifurcatio tracheae form a single plate.

Sperm whale: (fig. 5') In this whale the tracheal cartilages are complete rings, and the most cranial one is separate from the cricoid cartilage. The upper three cartilages are fused together in the dorsal parts, but the others are all separated from each other. The fact, that all of the tracheal cartilages form complete rings, seems to be an exception in the whales. For, according to Dubois, the uppermost one (*Hyperoodon*) or two (*Delphinus*, *Phocaena*) tracheal cartilages are lacking of its ventral portion, and also Watson and Young mentioned the same relation as to two or three upper cartilages respectively for *Beluga* and *Delphinus*.

II. Muscles of the larynx

Laryngeal muscles of the Cetacea have been studied by a number of anatomists, but their explanations are not always coincident. The difference of opinions come, to my mind, partly from difference of the materials treated. In fact, every species of the whales has more or less its own structure. We must naturally consider seriously the differences between toothed and whalebone whales. In the following my results upon laryngeal muscles of the Sei and the Sperm whale will be mentioned.

Sei whale:

As in the case of other mammals, the laryngeal muscles are classified also in this whale into two groups, extrinsic and intrinsic. The extrinsic

muscles, connecting the larynx with neighbouring structures, are:

Musculus sternothyreoideus (innervated by branches from the ansa hypoglossi)

Musculus thyreochoideus (ditto)

Musculus laryngopharyngicus (innervated by branches of the plexus pharyngicus)

Musculus hyoepiglotticus or baseohyoepiglotticus

The STERNOTHYREOIDEUS and the THYREOCHOIDEUS belong to the so-called infrahyoidal muscles and insert to the thyroid cartilage. The well developed LARYNGOPHARYNGICUS consists of THYREOPHARYNGICUS and CRICOPHARYNGICUS. The former arises from the frontolateral part of the inner surface of the thyroid cartilage and its massive fibres surround the pharynx to meet with that of the opposite at the posterior median part of the pharyngeal wall, i. e. raphe pharyngis. The latter originates from the dorsolateral part of the cricoid cartilage and, running up and medialwards, terminates also at the raphe pharyngis. The unpaired HYOEPIGLOTTICUS was described by Carte and Macalister (1868) in *Balaenoptera rostrata*, but I could not see it in the Sei whale.

The intrinsic muscles are those, which begin and end within the larynx itself. In the following I will describe them one by one.

(1) M. CRICOTHYREOIDEUS; (fig. 5) This muscle arises from the outer surface of the lateral process of the cricoid cartilage and runs upward and laterad, to insert on the medial border of the inferior horn of the thyroid cartilage. It is not divided into two parts, pars recta and pars obliqua, as in the human larynx. This muscle is the only one in the whole larynx, that is innervated by the cranial laryngeal nerve (fig. 18).

(2) M. CRICOARYTAENOIDEUS DORSALIS; (figs. 6, 7) This muscle arises mostly from the posterior medial portion of the cricoid cartilage, partially also from the caudal end of the inferior horn of the thyroid cartilage. Its fibres converge upwards and laterad to reach the muscular process of the arytenoid cartilage. Because of the connection with the inferior horn, it may be called better "m. ceratocricoarytaenoideus dorsalis", the name used already by Dubois.

(3) M. ARYTAENOIDEUS; (fig. 16) Tracing the fibres of m. cricoarytaenoideus dorsalis upwards, we come across muscle fibres running transversally between the arytenoid cartilages of both sides. The fibres arise

from the dorsolateral margin of the cranial process of the arytenoid cartilage on one side and attain the corresponding part of the same cartilage of the other side. This muscle (*m. arytaenoideus transversus* of Dubois) corresponds probably to the transversal part of *m. arytaenoideus* in the human larynx. The *pars obliqua* is not found in the cetacean larynx. According to Dubois the most caudal part of the arytenoidal muscle is covered by the upper part of the dorsal cricoarytenoid muscle, and moreover some fibres of the former are attached to the cricoid cartilage. On this point I agree with Dubois, though the boundary between these two muscles is not very distinct.

(4) Muscle of the walls of the laryngeal sack (*M. THYREOARYTAENOIDEUS*, *M. CRICOARYTAENOIDEUS LATERALIS*, *M. ARYEPIGLOTTICUS*, *M. THYREOPIGLOTTICUS*); (figs. 5, 8, 9, 12—17) As will be mentioned later, the Sei whale has a large sack attached to the ventral wall of the laryngotrachea. It communicates with the proper laryngeal cavity through a wide opening which exists between the arytenoid cartilages of both sides. This laryngeal sack has thick muscular walls and its muscles, cross-striated in nature, are arranged so differently from the laryngeal muscles in other animals, that it is not easy to determine the homologies between them.

Carte and Macalister examined for the first time these muscles in *Balaenoptera rostrata* with the conclusion that they belong to *m. thyreoarytaenoideus*. Dubois insisted that not only the thyreoarytenoid muscle but also the *m. cricoarytaenoideus lateralis* takes part in the formation of this muscular wall. Thereafter Benham, studying a newborn female *Balaenoptera rostrata*, supported Carte and Macalister's opinion and denied the co-existence of the lateral cricoarytenoid muscle.

At any rate these muscles exhibit quite strange arrangement in relation to the cartilages. In the Sei whale we see on the ventral surface of the larynx the *m. cricothyreoideus* on both sides. Moreover, massive muscle fibres come into sight from behind the caudal ridge of the thyroid cartilage, running downwards and being directed in the lateral parts somewhat laterad. These muscles, which form the ventral and lateral walls of the laryngeal sack, insert partly to the ventral ridges of the cricoid and tracheal cartilages, where these cartilages are defective in the ventral portion. More cephalic and deep fibres of them reach the muscular process of the arytenoid cartilage.

The comparatively superficial muscular layer of the laryngeal sack courses as a whole in the caudo-lateral direction; I would call it "A-group" in the following description.

A deeper group of muscle fibres arises mainly from the ventral surface of the caudal process of the arytenoid cartilage and, diverging downwards, forms a part of the ventral, lateral and to some extent the dorsal wall of the laryngeal sack ("B-group"). These fibres seem to have no insertion to any cartilage, terminating within the muscular wall itself. The ventral portion of them, running caudally and mediad, contrary to the caudal and lateral direction of the A-group, is interwoven in the median line between both sides!

Such a division of superficial and deep layers is however not so distinct, and they form altogether the very thick wall of the laryngeal sack. For this reason, the muscles were taken as a whole by Carte-Macalister and Benham as the thyreoarytenoid muscle, while Dubois regarded probably the B-group as the lateral cricoarytenoid muscle.

It seems certain from my observation that the walls of the laryngeal sack are mainly formed by the thyreoarytenoid muscle, but this muscle has, because of the extraordinary development of the sack, additional insertions to the cricoid and tracheal cartilages. As to the problem, whether the B-group corresponds to the lateral cricoarytenoid muscle, I can say nothing confidently. The bare fact is that the superficial fibres are directed somewhat differently than the deep fibres.

In addition to A- and B-group, some muscle fibres situated in a more cranial place arise from the inner surface of the thyroid cartilage and course almost horizontally, surrounding the sack from lateral to reach the middle ventral part of the arytenoid cartilage ("C-group"). We see besides other fibres in a more cranial level, connecting the basal part of the upper process of the arytenoid cartilage with the root of the epiglottis ("D-group"). These groups are however not very clearly separated from each other, but form as a whole the thick wall of the laryngeal sack. I guess that the D-group in my description may correspond to *M. ARYEPIGLOTTICUS* mentioned by Dubois and Benham respectively in the larynx of *B. Sibbaldii* and *B. rostrata*, or the superior and inferior arytenoepiglottic muscle described by Carte and Macalister in *B. rostrata*, while the C-group seems not to have been specially remarked by previous authors. They have pro-

bably considered this group merely as a part of the thyreoarytaenoideus.

The THYREOEPIGLOTTIC muscle, which extends between the root of the epiglottis and the cranial border of the thyroid cartilage, makes also a part of the muscular walls of the laryngeal sack.

Innervation of the laryngeal muscles (fig.18):

Of all the laryngeal muscles in the Sei whale only the cricothyreoideus receives the external branch of the N. LARYNGICUS CRANIALIS. This nerve descends along the lateral surface of the larynx and, changing its course slightly mediad, crosses over the thyroid cartilage. It comes down along the lateral ridge of the cricothyreoideus, and then terminates there. The internal branch of this nerve runs through the thick laryngopharyngeal muscle and ends in the mucous membrane of the larynx.

The N. LARYNGICUS CAUDALIS is considerably thick, ascends as the n. recurrens in the furrow between trachea and oesophagus, comes near to the inferior horn of the thyroid cartilage and, crossing over the here arising m. ceratocricoaerytaenoideus dorsalis, passes under this horn, to reach the laryngeal sack, where it is divided into several branches, some of which innervate the m. cricoarytaenoideus and others enter into the thick walls of the sack, ending in its muscles. The ending occurs in such a way, that the uppermost branches course under the caudal border of the thyroid cartilage and attain the m. arytaenoideus transversus; the next branches go to the C- and D-group; the lowermost branches, running in the caudal direction, terminate in the superficial and deep layers of A- and B-group, and we can trace their small branches macroscopically up to the half level of the sack.

Thus it is certain that, as all the muscles of the walls of the laryngeal sack are innervated by n. laryngicus caudalis, A-group of muscles, in spite of its insertion to the cricoid and tracheal cartilages, does not belong to the cricothyreoideus.

Sperm whale:

Extrinsic muscles

M. STERNOTHYREOIDEUS and M. THYREOHYOIDEUS: Connecting places of these muscles to the thyroid cartilage are shown in the accompanying figures (fig. 1'—a, b).

M. LARYNGOPHARYNGICUS: Of this muscle the thyreopharyngeal part is well developed, but the cricopharyngeal part is not found at all.

M. HYOEPIGLOTTICUS: This unpaired muscle arises from the hyoid bone (probably from its median part) and inserts to the ventral angle of the epiglottic cartilage.

M. PALATOPHARYNGICUS: The aryteno-epiglottideal tube, protruding into the choana, is encircled at the height of its neck by a muscular bundle, which lies within the choanal walls. This bundle, named by von Baer (1826) as the palatopharyngeal muscle, is well developed also in the Sperm whale. It must have an important meaning in relation to the function of the aryteno-epiglottideal tube. For, when it contracts, the communication between the naso-pharynx and the laryngeal cavity is shut out; at the same time the aditus laryngis must be closed completely. The meaning of such anatomical structures will be considered later.

Intrinsic muscles

(1) **M. CRICOTHYREOIDEUS:** Stannius (1848) and Rawitz described this muscle in *phocaena communis* as a small muscular bundle; also Dubois and Macalister (1867) remarked the same in *Hyperoodon* and *Globicephalus svineval* respectively. But according to Benham, this muscle was invisible in *Cogia*. In the Sperm whale, too, I could not ascertain its existence. Whether it is quite absent in this whale, I want to determine by further researches.

(2) **M. CRICOARYTAENOIDEUS DORSALIS:** (fig. 6') This is very well developed. As in the Sei whale not only the dorsal surface of the cricoid cartilage but also the inferior horn of the thyroid cartilage gives rise to this muscle (*m. ceratocricoaerytaenoideus dorsalis*). Its partial connection with the inferior horn was already reported by Stannius and Dubois, but Rawitz stated nothing about it.

I was much interested by the asymmetrical development of this muscle; namely it is very massive on the right side, but much poorer, though dilated considerably, on the left side. It must have some intimate relation with the asymmetry of the skull and nasal passage of this whale.

(3) **M. ARYTAENOIDEUS TRANSVERSUS:** (figs. 6', 7') This muscle, connecting transversely the arytenoid cartilages of both sides, is well developed. Its lowermost fibres insert to the cranial border of the cricoid cartilage.

The caudal boundary of this muscle is distinct against the upper fibres of *m. cricoarytaenoideus dorsalis*, the latter covering the former to some extent. This fact coincides well with Dubois' description on *B. physalus*. As mentioned already, the cricoidal insertion of *m. arytaenoideus transversus* is also present in the Sei whale: This relation, which according to Fürbringer (1875) never exists in the human larynx, seems to occur in the whales not rarely.

(4) *M. CRICOARYTAENOIDEUS LATERALIS*: This muscle was described by Stannius in *Phocaena*, by Murie in *Globicephalus melas* and by Benham in *Cogia*. But Meckel and Fürbringer denied the existence of it in *Delphinus delphis*. Watson and Young did not mention this muscle in *Beluga leucas* (cited from Dubois). Denying its existence in *Hyperoodon* and in other toothed whales, Dubois said that the so-called *m. cricoarytaenoideus lateralis* described by Stannius and Murie is nothing but a ceratal portion of the *m. cricoarytaenoideus dorsalis*. In the Sperm whale I too can not find this muscle.

I want to mention here my finding of a probably new muscle, which arises from the INNER surface of the body of the cricoid cartilage and inserts to the INNER surface of the arytenoid cartilage (fig. 9'). Though its attachments to the cartilages are not very firm compared with other muscles, it is certainly a special muscle clearly discernible from the surroundings. Its nature cannot be determined at present, but the fact itself is interesting that such an unusual cricoarytenoid muscle exists, deserving the name, "*m. cricoarytaenoideus internus*". Moreover there are several muscular fibres scattered on the inner surface of the thyroid cartilage, and I wondered whether the muscle above mentioned would be nothing but a collection of these fibres. But this assumption is not very probable, for the internal cricoarytenoid muscle is a bundle so distinctly isolated.

(5) *M. THYREOARYTAENOIDEUS*: (figs. 7', 8') This is a massive muscular bundle, which arises from an area along the caudal notch of the thyroid cartilage and inserts to the ventral and lateral surface of the muscular process of the arytenoid cartilage. As to locality and form, this muscle is not so unusual as in the Sei whale, for the laryngeal sack is absent in this whale.

(6) *M. THYREOEPIGLOTTICUS* and *M. ARYEPIGLOTTICUS*: Though Rawitz denied the existence of these muscles in *Phocaena communis*, Benham

found them in Cogia. In the Sperm whale I see no muscle fibres, which may deserve the names. The upper portion of the *m. thyreoarytaenoideus* comes in contact with the *petiolus epiglottidis*, but shows no direct connection to this. Absence of these muscles might be explained from the very firm ligamentous connection between epiglottis and thyroid cartilage, where almost no mobility seems to remain.

III. The laryngeal cavity

Sei whale :

The larynx of the Sei whale does not exhibit a tubal structure as in the toothed whales. As shown in fig. 10, the *aditus laryngis* of the Sei whale differs in its general form not much from that of the human being. Namely, the tongue-shaped epiglottis projects from the ventral surface of the pharyngeal cavity, with its apex directed somewhat upwards (about 12 cm high). From its lateral ridge on each side a fold of mucous membrane (*plica aryepiglottica*) is stretched, encircling the laryngeal aperture, dorsally and downwards to the arytenoid cartilage. The cranial processes of the arytenoid cartilages are connected between both sides by a part of mucous membrane; the apex, though projecting upwards a little, is situated much lower than that of the epiglottis.

The laryngeal cavity is in this whale a relatively narrow space surrounded by the paired arytenoid cartilages and the single cricoid cartilage behind. The mucous membrane, covering the inner surface, is generally smooth, but has a few fine grooves. This cavity passes downwards behind the caudal processes of the arytenoid cartilages, which are also connected between both sides, and continues further with the tracheal cavity.

The laryngeal sack (figs. 11, 13—17, 18) :

As related before, the laryngeal cavity has in the Sei whale a large sack-formed appendage, which is to be named "*saccus laryngis ventralis*". It is on the ventral wall of the larynx, elongated downwards through the whole length of the trachea, the ventral clefts of cricotracheal cartilages offering a space just fitted for this sack. The constituents of the thick muscular wall of this sack were already mentioned in the precedent chapter. The cavity within the sack is elongated longitudinally and communicates with the proper *cavum laryngis* through a slit along nearly the whole length

of the arytenoid cartilage. The inner surface of the sack has much folds and grooves, as shown in fig. 11. There are many longitudinal folds in the upper part, while the lower parts show many reticulated grooves and the meshes are especially fine on the dorsal wall. We see many granular prominences here on the mucous membrane. In the ventral parts the folds and grooves are considerably rough. Judging from this structure, it seems doubtless that this sack is liable to extension and contraction in the living whale.

It is naturally important to know the function of this highly contractile laryngeal sack. I will consider this problem at first historically.

The honour of the discovery of the laryngeal sack is ascribed to J. Hunter, as this great anatomist stated in his study on *Balaenoptera rostrata*, that a sack is present on the ventral surface of the larynx.

Since then the laryngeal sack has been observed by Eschricht and Reinhardt (1866) in *Balaena mysticetus* and by Carte and Macalister, and Benham in *Balaenoptera rostrata*. Beuregard and Boulart (1882), who examined the laryngeal sack in *Balaenoptera musculus*, *B. physalus* and *Balaena antipodum*, noticed the difference that the sack in question is far smaller in *Balaenidae* than in *Balaenopteridae*. In the Sei whale Schulte (1916) touched this sack briefly.

The fact that this laryngeal sack is present only in the whalebone whales, was indicated for the first time by Eschricht and Reinhardt. Dubois, comparing between *B. physalus* and several kinds of toothed whales, ascertained this. Rawitz, too, mentioned this fact, when he studied the larynx of *Phocaena communis*.

In the meantime the problems, what is the anatomical nature of the laryngeal sack and why this sack exists only in the whalebone whales, have been very differently answered. Dubois regarded this sack as homologous with the Morgagni's ventricle. He came to this opinion by comparing the laryngeal structure of toothed whales, because these animals have no laryngeal sack on the ventral wall of the larynx, but have a recess on each side of the median longitudinal membranous fold; and he explained this recess as corresponding to the Morgagni's ventricle. Dubois thought that the laryngeal sack of whalebone whales is formed by the further enlargement of the recess, extension of its walls and by development of the thyreoarytenoid muscle.

But Benham doubted the homogeneity of the laryngeal sack of whalebone whales with the laryngeal recess of toothed whales, though he accepted the correspondence of the recess with the Morgagni's ventricle. Such a problem is very difficult to decide, for the two structures, both of which are appendages of the laryngeal cavity, differ very much from each other especially in their relation to muscles and cartilages. On the other hand, there are undeniable communities between them, in spite of the differences in size, form and structure of the walls.

A key for settling the problem may probably lie in the fact, that the laryngeal sack for Balaenidae and Megapteridae is not so large as that of Balaenopteridae, showing, so to speak, an intermediate form between the laryngeal recess and the laryngeal sack. I myself ascertained the smallness of the laryngeal sack in a fetus of *Megaptera nodosa*.

Now, on the function of the laryngeal sack there seem to be three possibilities as follows.

First, it may be possible that this is an apparatus for preventing the entrance of water and food into the respiratory canal, as the contraction of massive muscles of this sack will make the laryngeal sack, at the same time the larynx itself firm and solid, so as to avoid mis-swallowing of a large quantity of food with water into the larynx and trachea. Rawitz, for instance, stated this opinion. Prof. Ogawa has also an opinion near but a little different to this, for he thinks that the blow of air produced by contraction of the laryngeal sack will prevent the entrance of water and food into the respiratory canal.

The second possibility is, that this sack may concern with complete utilization of oxygen in the inspired air. Schulte said in his paper on a fetus of the Sei whale, "that by its contraction and relaxation during submergence, a circulation of air in the wide trachea and bronchi might be set up, which would favor the absorption of oxygen by bringing the air in these passages more rapidly into contact with the respiratory membrane than could be done by the usual diffusion currents". Another very interesting opinion related to the second possibility was stated by Negus in his book titled "The Mechanism of the Larynx", that all the air-sacs communicated with the respiratory canal of animals must be for the "rebreathing of air". To explain the "rebreathing of air", he took up the frog as an example, saying "a frog kept under water for a prolonged period expels air

from its lungs into its mouth and pharynx; the used-up air which has been in contact with the pulmonary epithelium mixes with the relatively unused air which has lain in the centre of the sac-like lungs. This mixed air, when blown back into the lungs, gives up a fresh supply of oxygen and takes up CO₂, so that respiration can be continued for a time without the intake of a fresh supply of air". According to him, the laryngeal air sacs not only of the aquatic animals including sea-lion, whales etc., but also of the terrestrial animals are for this purpose.

The third possibility is the relation of this sack with the phonation. The Sei whale has no vocal cord in the larynx; its absence is also proved in other whalebone and toothed whales. And so, it is generally believed that the whales produce no voice. Some authors however insisted upon voices of whales (Schneider, 1795; Murie; Rawitz). Turner (1872) explained the mechanism of phonation in Balaenidae as such, that the elongated caudal processes of the arytenoid cartilages are drawn near to each other and vibrate by the strong expiration of whales. This opinion was accepted by Weber and Dubois, and was, though denied by Rawitz, adopted again by Göppert in Bolk's "Handbuch der vergleichenden Anatomie" (1937). If such a mechanism of phonation be true, we must hold in mind the utility of the laryngeal sack in this function.

At present it is impossible to determine, which of these three be the fact. Moreover the truth may lie outside of them.

Relation of the laryngeal sack with the internal structure of the brain (fig. 19):

While the Sei whale has a large laryngeal sack, the Sperm whale has not such a sack. Probably relating to this difference, a remarkable different structure was found in the medulla oblongata of whales. Namely, the nucleus ambiguus is poorly developed in the pigmy Sperm whale, *Cogia breviceps* (Fig. 12'), while the same nucleus shows in the Sei whale such a striking development that the name "ambiguus" is very unsuitable for this animal. Prof. Ogawa (1948) has directed his attention for the first time to this fact and ascribed the extraordinary development of this nucleus in the Sei whale to the large laryngeal sack. For the massive muscular sheets of this sack are innervated by the vagus and it is generally believed that the nerves innervating laryngeal muscles arise from the nucleus ambiguus.

To make this problem more definite, we must examine in the future the brains of Megapteridae and Balaenidae, for the laryngeal sack of them is, as already mentioned, much smaller than that of Balaenopteridae, but larger than the laryngeal recess of toothed whales.

Sperm whale :

The entrance to the larynx is in this whale a transverse fissure at the top of the aryteno-epiglottideal tube, which protrudes into the choana and is encircled at its neck by circular fibres of the palatopharyngeal muscle. The larynx of the Sperm whale shows therefore the well known characteristic of various toothed whales (figs. 7', 10').

Figure 11' shows the inner surface of the laryngeal cavity. In this sketch the whole larynx except the epiglottic cartilage is cut in the median plane and the right half is removed. The cavity communicates above with nasal cavity through the laryngeal aperture and below with the tracheal canal, while the greater part of this cavity belongs to the aryteno-epiglottideal tube. Along the median line of the ventral wall, we see a longitudinal elevation covering the median crest of the epiglottic cartilage. The mucous membrane of the laryngeal cavity has numerous fine furrows and folds. Very fine furrows run longitudinally in the upper half of this cavity and between them many minute points or holes are seen in rows. The mucous membrane, which covers the medial surface of the arytenoid cartilage is quite smooth, lacking of furrows. In the lower parts, near the trachea, there are fine reticular furrows and folds, while the part covering the median crest of the arytenoid cartilage has oblique or looped furrows.

From the caudal end of the median crest a membranous fold (*plica mediana*) runs to the cranial and ventral border of the cricoid cartilage and we see here a triangular recess on each side of this fold. The furrows are relatively rough in this part and many lacunae are present, which seem to be apertures of the lymphatic nodules.*

This triangular recess was already referred to in relation to the laryngeal sack. The opinion that this recess would correspond to Morgagni's ventricle in other mammals was stated for the first time by Murie in his

* The inner surface of the laryngeal sack of the Sei whale does not show such lacunae, but I found many relatively larger lacunae on the ventral surface of the membrane connecting the upper ends of the cranial processes of the arytenoid cartilages of both sides. (fig. 12)

paper on *Globicephalus melas*. Watson and Young published the same opinion for *Beluga leucas* (cited from Dubois) and Dubois also accepted it.

Physiological meaning of the aryteno-epiglottideal tube:

The opinion has been prevalent, that the toothed whales can swallow and respire at the same time owing to this peculiar structure, for the alimentary and the respiratory canal can be in this way completely separated from each other. This opinion seems to have its origin in Camper (1820), and was supported by Milne-Edward (1860), Gegenbaur (1891), Zuckerkandl (1898) (cited from Boenninghaus) and Negus (1928). But it had not so definite basis and was opposed to by Boenninghaus from anatomical and physiological reasons. According to him, all the mammals must dilate its pharynx at deglutition and simultaneously the larynx must be shut off as a reflex by contraction of the laryngeal muscles. My observations upon the larynx of the Sperm whale justify more the opinion of Boenninghaus. I want to suggest, that, when the palatopharyngeal muscle is contracted at deglutition to avert the entrance of food and water into the choana, the laryngeal aperture also must be closed, so there would occur no respiratory action. Besides, I suppose, the Sperm whale would have no need to be able to swallow and respire at the same time, because this whale used to take its food in the depth of sea. Taking in mind the high pressure of water there, it seems very probable that such a tubal apparatus is exclusively to avoid the mis-swallowing of food and water into choana and larynx, rather than to swallow and respire simultaneously.

Another somewhat different opinion was offered by Huber (1934), who stated in his paper on the nasal passage of Tursiops, that the palatopharyngeal muscle around the aryteno-epiglottideal tube, together with the m. maxillonasolabialis around the blow-hole and the muscular plug in the osseous nasal passage, belongs to the blow-hole mechanism, which performs the task to shut the nasal passage closely, so as to avoid the entrance of water into lungs, when the whale submerges into the depth of sea. At any rate, it is quite reasonable, also from the standpoint of dynamics, to close the laryngeal aperture by contracting the neck of this tube by the palato-pharyngeal muscle.

As an appendix to this work I wish to say briefly about the Phonation

of Whales.

Neither the Sperm whale nor the Sei whale has the vocal cord in the larynx. Absence of the vocal cord in whales has been written by many authors, for instance by Meckel for *Delphinus* and *Phocaena*, by Cuvier, Stannius, Milne-Edward etc. for various kinds of whales, and Hunter insisted that the whales do not possess the ability of crying. But Schneider stated, in opposite to Hunter, that he heard from a "Grönlandfahrer" about crying of whales and Murie said in his paper on *Grampus rissoanus*, "that some species of whales utter sound is now unquestioned, notably the species under consideration and the ca'ing whale (*Globicephalus melas*)".

How can the whale then make sound without the vocal cord? Murie thought, taking the membranous folds above mentioned- two folds are said to exist in the larynx of *Grampus*- as the substitute for the vocal cord, that the forcible blow or expiration of the whale would vibrate these folds, producing sound. He added furthermore that in some animals, for instance, *Hyomoschus aquaticus* and *Saiga tartaria*, the vocal cords are placed nearly vertically on the sides of the larynx, similarly as in the cetacean larynx.

Concerning the whalebone whales, Milne-Edward (1876) said that they would be dumb, but Turner, Watson, Young and Dubois accepted the possibility of them to make sound. They explained that the caudal process of the arytenoid cartilage would be vibrated by the exblows of the whale, producing thus voices. Dubois added furthermore that perhaps a similar modus of phonation is possible also for *Otaria gillespii*. Though Rawitz mentioned, opposing to Turner etc., that it is impossible for a cartilaginous substance to vibrate and produce voice, yet he believed the ability of whales to make voice, especially of *Megaptera boops*. According to him, the organ of phonation is in the whales not the arytenoid cartilage but membranous folds formed temporarily in the larynx or in the soft palate, especially during the rutting season.

So far I have reviewed the opinions and possibilities published by various authors on the phonation of whales, but, regret to say, that the final solution of this problem is far beyond us. But it seems doubtless that some dolphins can make sound, though it might be faint. Of the whalebone whales I have not been told by any whaler that he heard the voice of whales. During my Antarctic whaling trip (1947—1948), I had no

opportunity to experience the voice of whales. Even when they were hurted by the harpoon, they did not cry at all. If they could produce voice, I supposed, judging from the situation, that they would make voices in such cases. Of course it is not impossible that the whales produce sound and communicate between them especially during the rutting season. Even at that time the sound might be so faint that it does not deserve to be called "voice"; but it would be sufficient for the communication between them; the vibration will be propagated in the water and received by their sensitive auditory organs. If so, there is no need for us to seek for any special vocal organ in the larynx, for such a vibration could be produced without the vocal cord from other parts of the body. At any rate it would be necessary to know the nature of the voice of whales, its relation to the breeding season and so forth.

IV. Comparison of the larynx between the Sei and the Sperm whale

From the foregoing description I will point out the remarkable differences in the larynx of the Sei and the Sperm whale.

	Sei whale	Sperm whale
Thyroid cartilage	Relatively small, without the median angle.	Of a large size, with a remarkable median angle.
Epiglottic cartilage	Relatively small.	Well developed and elongated upwards.
Arytenoid cartilages	Caudal process is well developed and its apex is connected with that of the other side.	Cranial process is continuous between both sides at the upper end. The caudal process is absent.
Cricoid cartilage	Ventral half is widely lacking and continuous downwards to the tracheal cartilages.	Completely ring-formed.
Tracheal cartilages	Ventral parts are widely lacking.	Completely ring-shaped.
Thyrearytenoid muscle	Long and wide, forming the walls of the laryngeal sack.	An ordinary muscle bundle.
Laryngeal sack	Of very large size.	Lacking, but provided with a small recess on each side.
Aryteno-epiglottideal tube	Lacking perfectly.	Well developed, typical for the toothed whales.
Asymmetry of the laryngeal structure	Almost symmetrical.	Somewhat asymmetrical (for example, development of <i>m. cricoarytaenoideus dorsalis</i>).

From this table, it may be concluded that the most important difference lies in the remarkable development of the laryngeal sack of the Sei whale and in the typical aryteno-epiglottideal tube in the Sperm whale. For, almost all of other differences are more or less in relation to these features, which are at the same time the characteristic respectively of the whalebone and of the toothed whales.

As the last problem, I wish to consider, why such a tubal structure of the larynx exists only in the toothed whales? And why is the laryngeal sack present only in the whalebone whales? These problems, I suppose, cannot be answered merely from the functional standpoint, but are concerned in a high degree also with the phylogenetic relation. In other words such remarkable differences in the larynx between toothed and whalebone whales is not to be explained solely as acquired characteristics during the aquatic life.

The interrelationship between these two groups of whales does not seem to be so close, and the resemblance of their external form might be rather explained as a convergence of organisms; for, the inner structures of them are, in some points, too much different to be regarded as intimately related. Concerning the relationship between the toothed and the whalebone whales, Dubois remarked that "der Larynx der Odontoceti steht dem ursprünglichen Typen näher, während derjenige der Mystacoceti sich weiter entfernt hat". Rawitz opposed to this opinion and said, "dass Odontoceten- und Mystacoceten-larynx sich nicht aus einander entwickelt haben können, dass der erstere nicht die Vorstufe des letzteren darstellt, dass aber das umgekehrte Verhältnis nicht statthat. Und daraus folgt, dass sie aber an der Wurzel nicht einander zusammenhängen, nicht direkter Verwandtschaft mit einander stehen", and I myself agree with Rawitz's opinion. Pütter (1902) also stated approximate ideas in his comparative anatomical work upon the eyes of marine mammals.

Summary and Conclusions

- 1) As to the laryngeal cartilages and muscles, many remarkable differences are found between the Sei and the Sperm whale.
- 2) The larynx of the Sei whale shows the most noteworthy characteristic in the presence of an enormous muscular sack on its ventral side, saccus laryngis ventralis, and almost all of the peculiarities of its cartilages and

muscles are more or less concerned with this laryngeal sack.

- 3) Four muscle-groups (A, B, C, D) were classified in the muscular walls of the laryngeal sack, with considerations upon their homogeneity with the laryngeal muscles of other mammals.
- 4) These muscle-groups of the laryngeal sack are all innervated by the caudal laryngeal nerve.
- 5) The extraordinarily well developed nucleus ambiguus in the medulla oblongata of the Sei whale seems to be intimately related with the action of this laryngeal sack, which is probably able to contract and dilate in a considerable degree. The corresponding nucleus is not well developed in the toothed whales, which lack of the laryngeal sack.
- 6) The general characteristic of the larynx of the toothed whales, including the Sperm whale, lies in the upward elongated epiglottis and arytenoid cartilage, which form altogether the aryteno-epiglottideal tube.
- 7) Some asymmetrical relations were noticed in the larynx of the Sperm whale, for instance in the development of the dorsal cricoarytenoid muscle and in the relative position of oesophagus to the larynx. These asymmetries may be related with the extraordinarily asymmetrical nasal passages of this whale.
- 8) With the completely ring-formed cricoid and tracheal cartilages, the Sperm whale is, together with *Cogia* and *Tursiops*, an exceptional case in the realm of *Odontoceti*, for these cartilages have a median cleft in the ventral portion in almost all of the toothed whales.
- 9) The lateral cricoarytenoid muscle was not found at all in the Sperm whale, but I saw a muscle bundle, probably not yet known, deserving the name "*m. cricoarytaenoideus internus*".
- 10) The remarkable differences in the larynx between the whalebone and toothed whales cannot be explained merely from the adaptation of these whale to the aquatic life, but must be rather referred to the phylogenetic relation; namely, I believe, coincidentally with some previous authors, that the two groups of whales, whalebone and toothed whales, are not so intimately kindred to each other as generally assumed.

Explanation of figures :

Sei whale

- Fig. 1, Thyroid cartilage
 Fig. 2, Epiglottic cartilage
 Fig. 3, Cricoid and tracheal cartilages
 Fig. 4, Arytenoid cartilage
 Fig. 5, Larynx (ventral view)
 Fig. 6, Larynx (dorsal view)
 Fig. 7, Larynx (dorsolateral view)
 Fig. 8, Larynx (the ventral right quarter is removed)
 Fig. 9, Median section through the larynx
 Fig. 10, Laryngeal aperture
 Fig. 11, Laryngeal sack (inner surface)
 Fig. 12, Lymphatic lacunae on the ventral surface of the membrane connecting the cranial processes of the arytenoid cartilages
 Fig. 13, Horizontal section through the larynx (1)
 Fig. 14, Horizontal section through the larynx (2)
 Fig. 15, Horizontal section through the larynx (3)
 Fig. 16, Horizontal section through the larynx (4)
 Fig. 17, Horizontal section through the larynx (5)
 Fig. 18, Innervation of the laryngeal muscles
 Fig. 19, Nucleus ambiguus

Sperm whale

- Fig. 1', Thyroid cartilage
 Fig. 2', Epiglottic cartilage
 Fig. 3', Cricoid cartilage
 Fig. 4', Arytenoid cartilage
 Fig. 5', Tracheal cartilages
 Fig. 6', Larynx (dorsal view)
 Fig. 7', Larynx (dorsolateral view)
 Fig. 8', Larynx (lateral view, the right lamina of the thyroid cartilage is removed)
 Fig. 9', *M. cricoarytaenoideus internus*
 Fig. 10', Laryngeal aperture
 Fig. 11', Laryngeal cavity
 Fig. 12', Nucleus ambiguus of the pigmy Sperm whale (*Cogia breviceps*)

Literature cited

- 1) Tyson, E.; *Phocaena, or the anatomy of a porpoise, dissected at Gresham college etc.* London. 1680. (cited from Rawitz)
- 2) Hunter, J.; *Observations on the structure and oeconomy of whales.* Philos. Transact. Roy. Soc. London. Vol. 16 (1785—90). 1787. pp. 306—351.
- 3) Schneider, J. G.; *Beiträge zur Naturgeschichte der Walfischarten.* Leipzig. 1795.
- 4) Camper, P.; *Observations anatomiques sur la structure intérieure et le squelette de plusieurs espèces des Cétacés.* Paris. 1820. (cited from Rawitz)
- 5) Baer, K. E.; *Ueber den Braunfisch (Delphinus phocaena).* Isis von Oken. Jahrgang 1826. Bd. 1. Heft 1—6. 1826. (cited from Rawitz)
- 6) Meckèl, J. F.; *System der vergleichenden Anatomie.* 6. Teil. 1833.
- 7) Cuvier, G.; *Leçons d'anatomie comparée.* Tome 4. Première partie. 1835.
- 8) Stannius, H.; *Lehrbuch der vergleichenden Anatomie.* 2. Teil. 1846.
- 9) Stannius, H.; *Beschreibung der Muskeln des Tümmlers (Delphinus phocaena).* Müller's Archiv für Anatomie 1849. (cited from Dubois)
- 10) Eschricht, D. F. and Reinhardt, J.; *On the Greenland Right-whale (Balaena mysticetus).* Ray Society. Recent memoirs on the cetacea. 1866. pp. 1—150.
- 11) Macalister, A.; *On some points in the anatomy of Globicephalus siveval (Gray).* Proc. Zool. Soc. London. 1867. pp. 477—482.
- 12) Burmeister; *Preliminary observations on the anatomy of Pontoporia blainvillii.* Proc. Zool. Soc. London. 1867. pp. 484—489.
- 13) Burmeister; *Preliminary Description of a new species of Finner Whale (Balaenoptera bonaërensis).* Proc. Zool. Soc. London. 1867. pp. 707—713.
- 14) Turner, W.; *A contribution to the anatomy of the Pilot Whale (Globicephalus siveval, Lacépède).* Journ. Anat. Physiol. Vol. 2 (second series, Vol. 1). 1868. pp. 66—79.
- 15) Carte, A. and Macalister, A.; *On the anatomy of Balaenoptera rostrata.* Philos. Transact. Roy. Soc. London. Vol. 158. 1868. pp. 201—261.
- 16) Murie, J.; *On Risso's Gramus, G. rissoanus (Desm.).* Journ. Anat. Physiol. Vol. 5. 1871. pp. 118—138.
- 17) Turner, W.; *An Account of the Great Finner Whale (Balaenoptera Sibbaldii) stranded at Longneddery. Part 1. The soft parts.* Transact. Roy. Soc. Edinburgh. Vol. 26. 1872. p. 197. (cited from Dubois)
- 18) Murie, J.; *On the Organisation of the Caaing whale (Globicephalus melas).* Transact. Zool. Soc. London. 1874. Vol. 8. p. 236. (cited from Dubois)
- 19) Milne-Edwards, H.; *Leçons sur la physiologie et l'anatomie comparée de l'homme et des animaux.* Tome 2. Paris. 1876.
- 20) Fürbringer, M.; *Beiträge zur Kenntnis der Kehlkopfmuskulatur.* Jena. 1879.
- 21) Sanctis, L.; *Monografia zootomica zoologica sul capidoglio arenato a Porto St. Giorgio.* Atti de Lincei Mem. Cl. Sc. fis. ecc. Ser. 3. Vol. 9. 1879. p. 160. (cited from Dubois)
- 22) Watson, M. and Young, A. H.; *The anatomy of the Northern Beluga (Beluga catodon, Gray, s. Delphinapterus leucas Pallas) compared with that of other Whales.* Transact. Roy. Soc. Edinburgh. Vol. 29. Part 1. 1878—79. (cited from Dubois)

- 23) Howes, G. B.; On some points in the anatomy of the Porpoise (*Phocaena communis*). Journ. Anat. Physiol. Vol. 14. 1879. pp. 467—474.
- 24) Beauregard, H. et Boulart, R.; Recherches sur le larynx et la trachée des Balenides. Journ. de l'anatomie et de la physiologie. Vol. 18. 1882. pp. 611—634.
- 25) Weber, M.; Studien über Säugethiere, ein Beitrag zur Frage nach dem Ursprung der Cetaceen. Jena. 1886.
- 26) Dubois, E.; Ueber den Larynx (der Cetaceen). Weber's "Studien über Säugethiere". 1886. pp. 88—111.
- 27) Rawitz, B.; Die Anatomie des Kehlkopfes und der Nase von *Phocaena communis* Cuv. Internat. Monatsschrift für Anat. u. Physiol. Bd. 17. 1900. pp. 245—354.
- 28) Benham, W. B.; On the larynx of certain whales (*Cogia*, *Balaenoptera* and *Ziphius*). Proc. Zool. Soc. London. 1901. I. pp. 286—300.
- 29) Boenninghaus, G.; Der Rachen von *Phocaena communis*, Less. Zool. Jahrbücher. Bd. 17. 1902 (1903). pp. 1—98.
- 30) Pütter, A.; Die Augen der Wassersäugethiere. Zool. Jahrb. Bd. 17. 1902 (1903). pp. 99—392.
- 31) Schulte, H. W. von; Anatomy of a fetus of *Balaenoptera borealis*. Memoirs of the American Museum of National History. New Series. Vol. 1. Part 6. New York. 1916. pp. 389—502.
- 32) Negus; The mechanism of the larynx. London and Tombridge. 1928.
- 33) Huber, E.; Anatomical notes on Pinnipedia and Cetacea. Contributions to Palaeontology IV. Carnegie Institution of Washington, Publications. No. 447. 1934. pp. 106—136.
- 34) Bolk und Lubosch; Handbuch der vergleichenden Anatomie der Wirbeltiere. Bd. 3. Kehlkopf. (by Göppert). 1937.

Fig. 1. Cart. thyreoides (1/8)

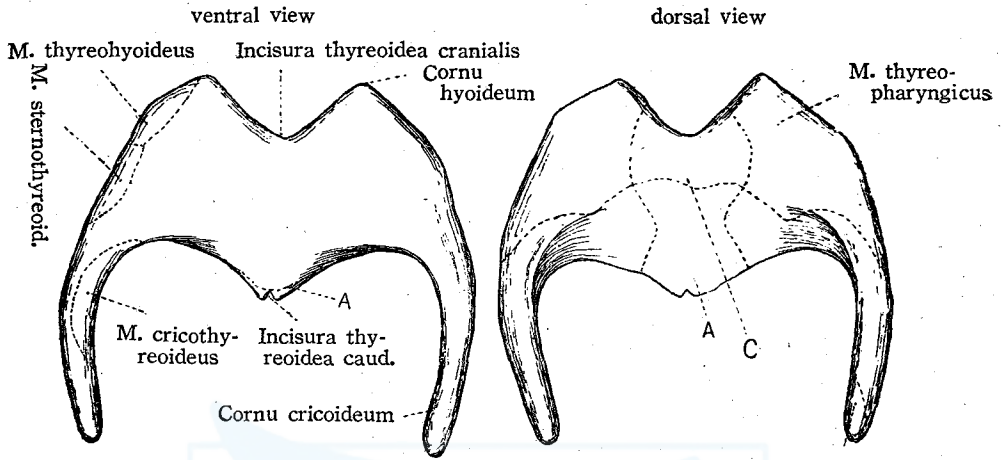


Fig. 2. Cartilago epiglottidis (1/4)

dorsal view lateral view



Fig. 3. Cart. cricoides et Cartt. tracheales (1/8) dorso-lateral view

M. cricoaryt. dorsalis

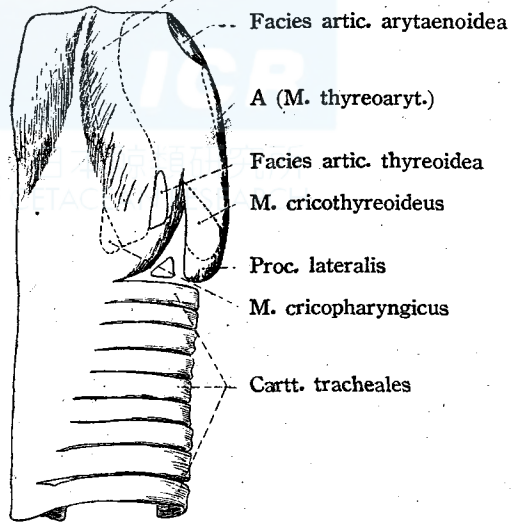


Fig. 4. Cart. arytaenoides (dextra) (1/8)

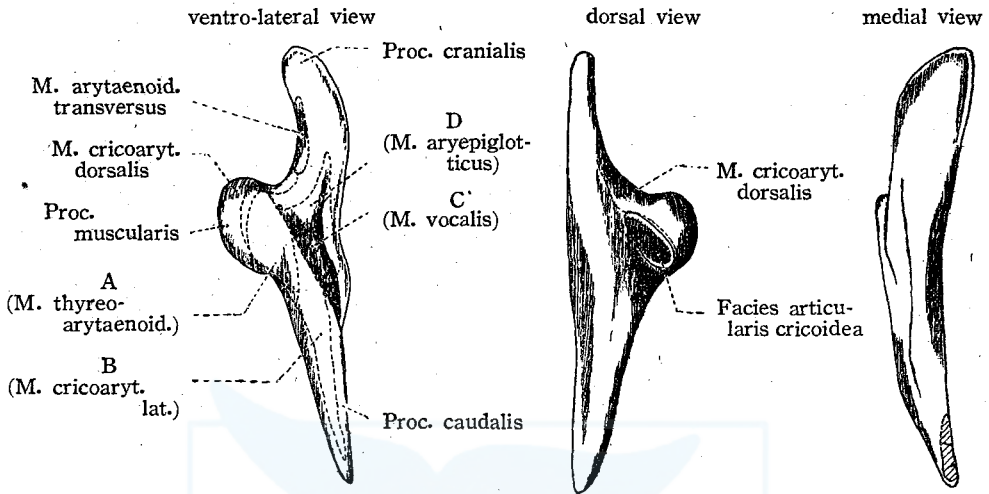


Fig. 5. Larynx ventral view (1/6)

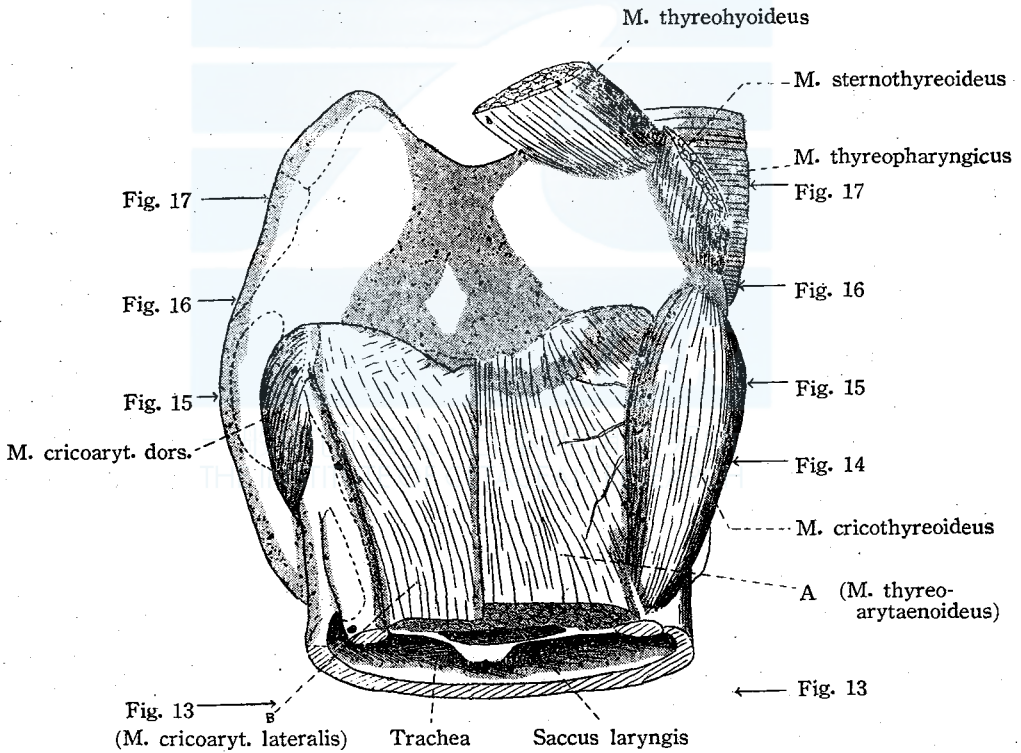


Fig. 6. Larynx dorsal view (2/15)
Raphe pharyngis

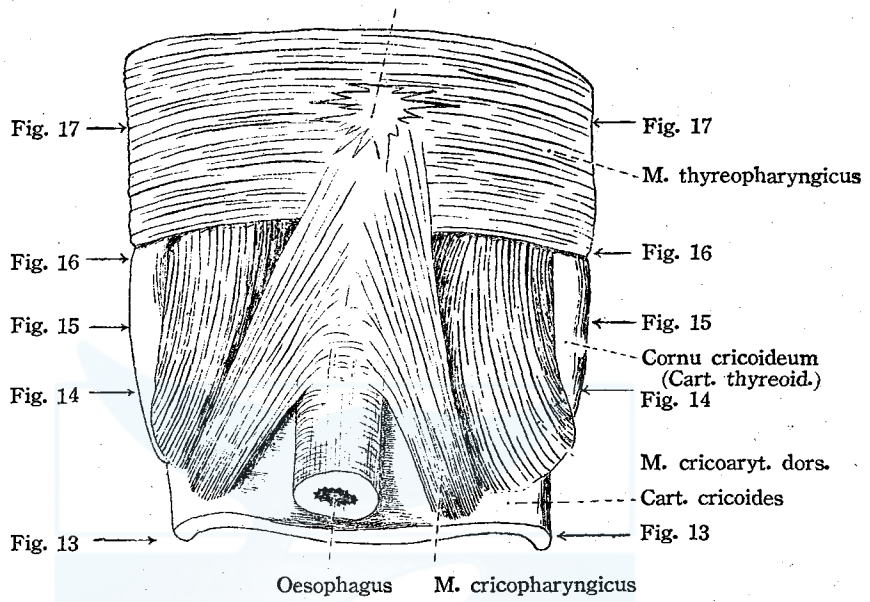


Fig. 7. Larynx dorso-lateral view (2/15)

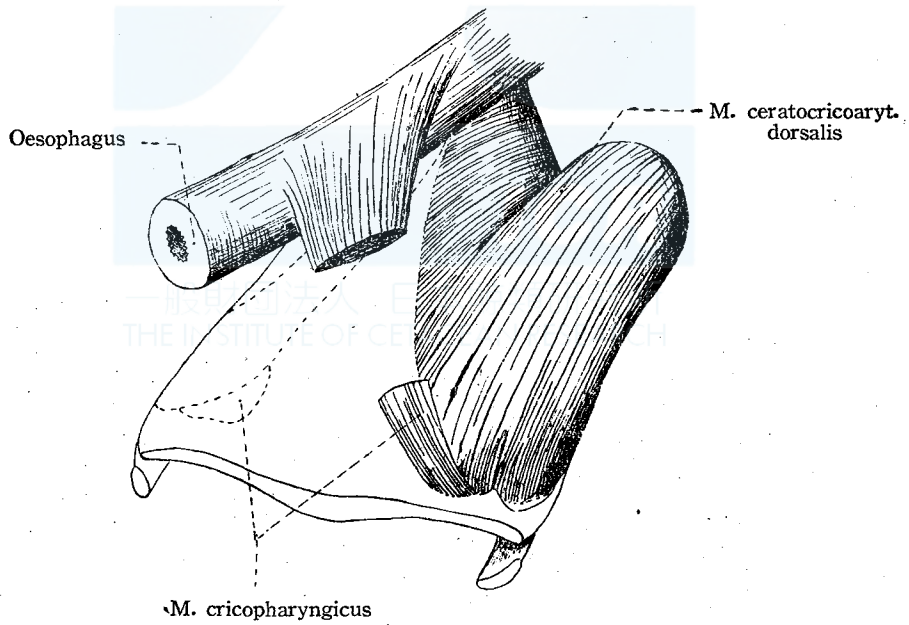


Fig. 8. Larynx (the ventral right quarter is removed) (2/15)

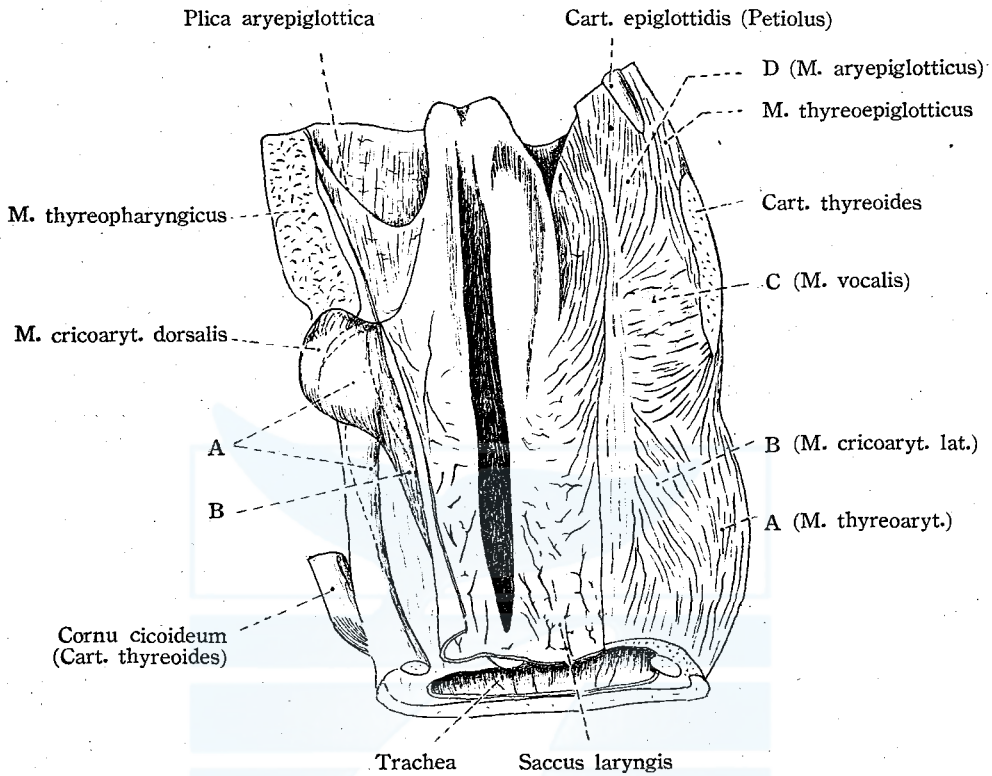


Fig. 9. Median section through the larynx (1/8)

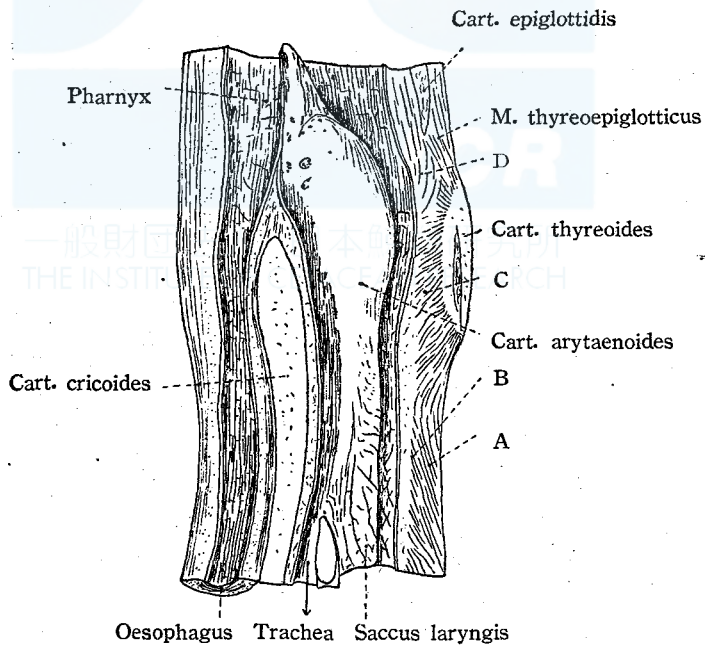


Fig. 10. Aditus laryngis (1/6)

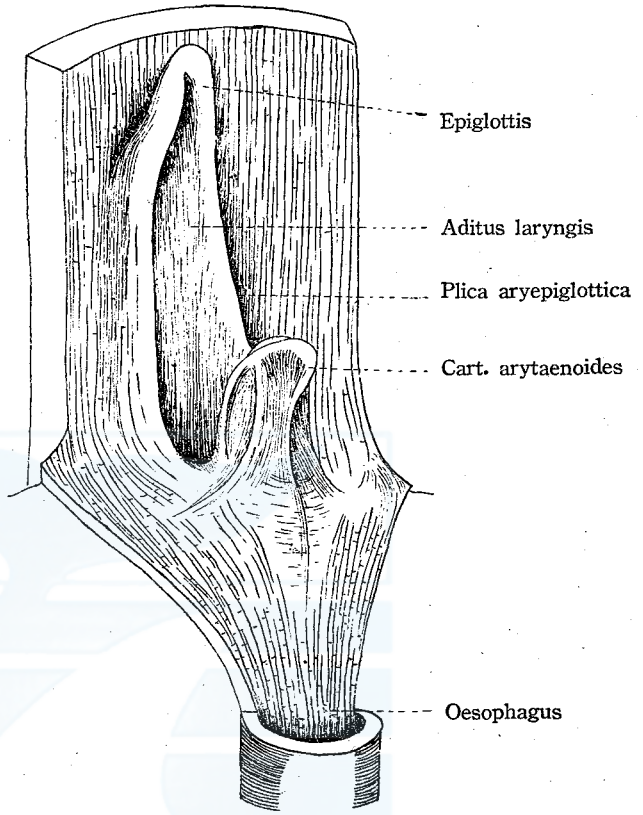


Fig. 11. Saccus laryngis inner surface (1/6)

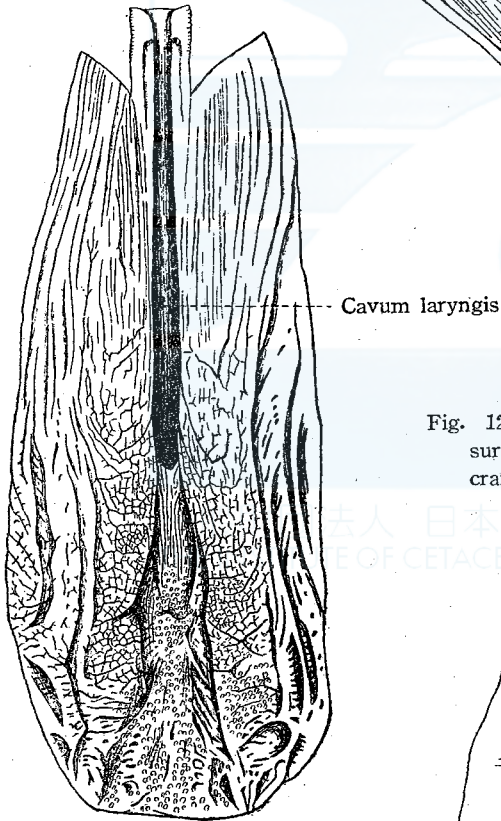


Fig. 12. Lymphatic lacunae on the ventral surface of the membrane connecting the cranial processes of the arytaenoid cartiages (1/4)

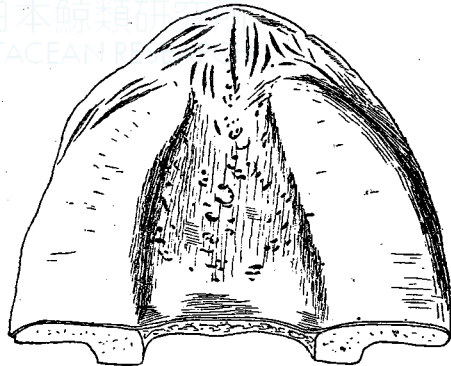


Fig. 13. Horizontal section through the larynx (1) (2/9)

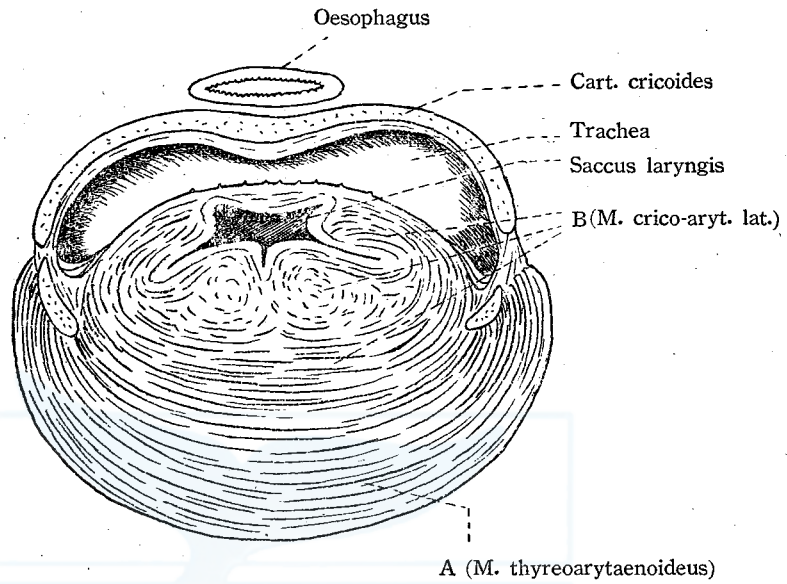


Fig. 14. Horizontal section through the larynx (2) (2/9)

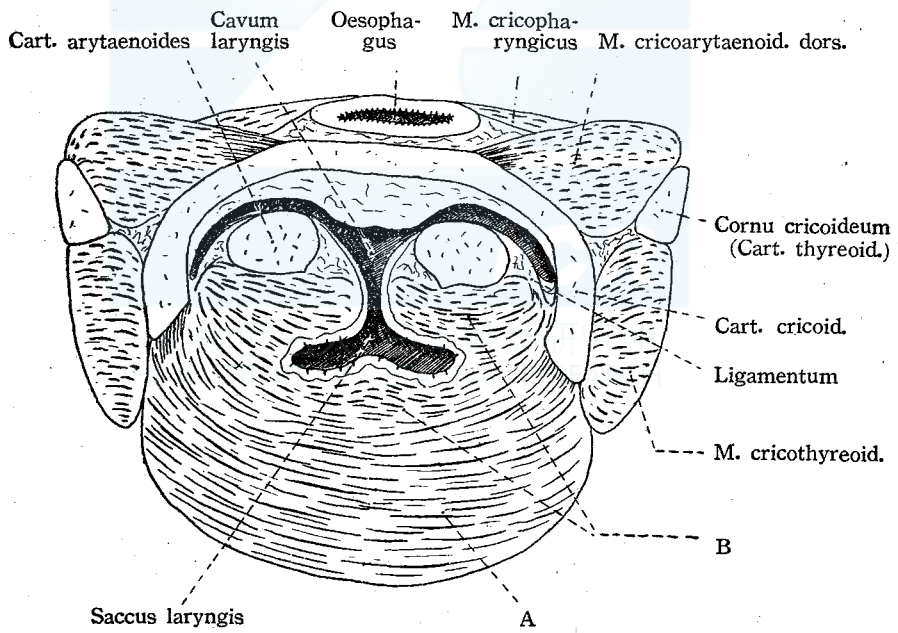


Fig. 15. Horizontal section through the larynx (3) (2/9)

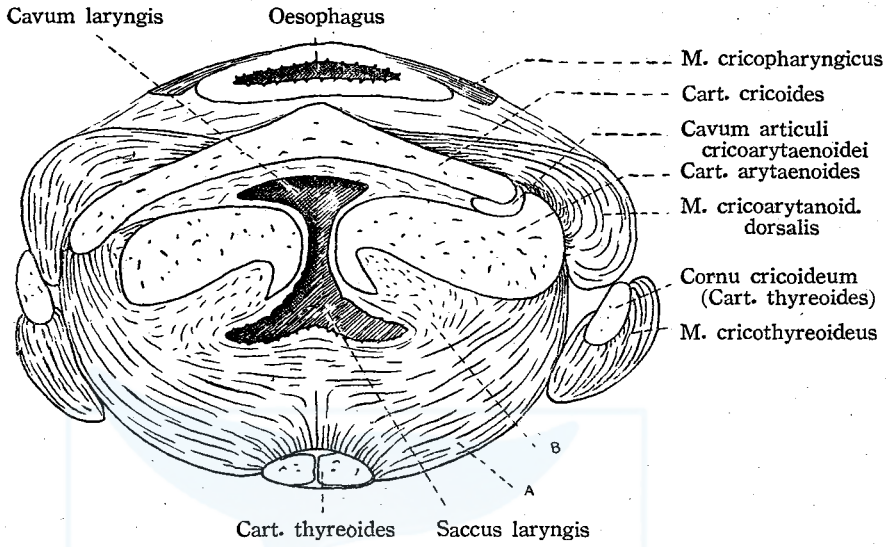


Fig. 16. Horizontal section through the larynx (4) (2/9)

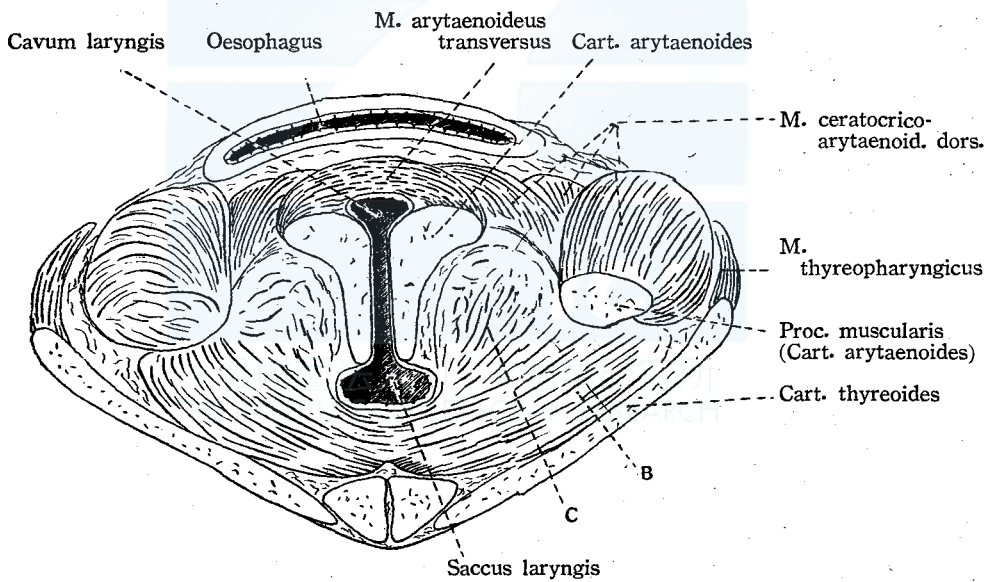


Fig. 17. Horizontal section through the larynx (5) (2/9)

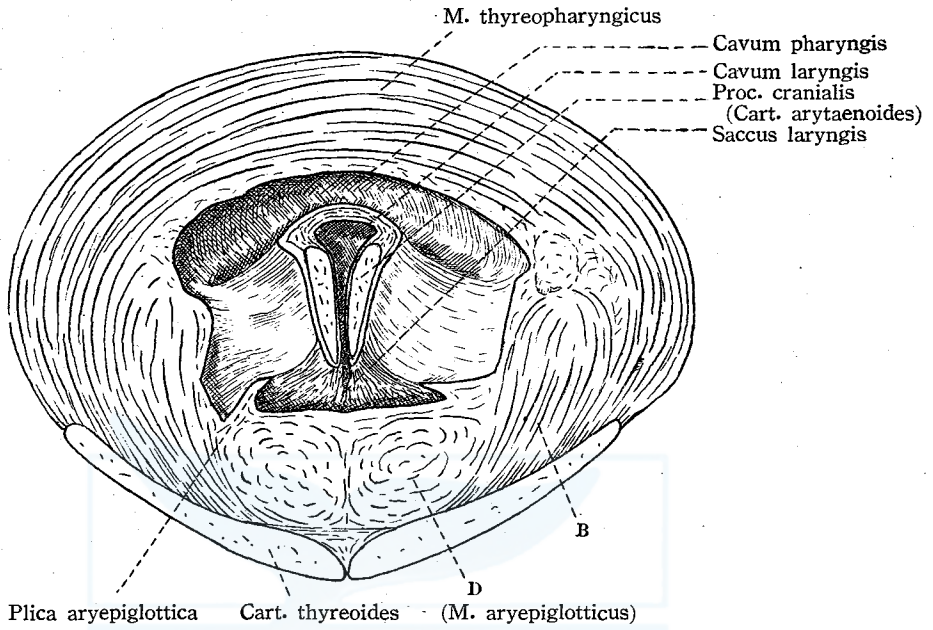


Fig. 18. Innervation of the laryngeal muscles (2/15)

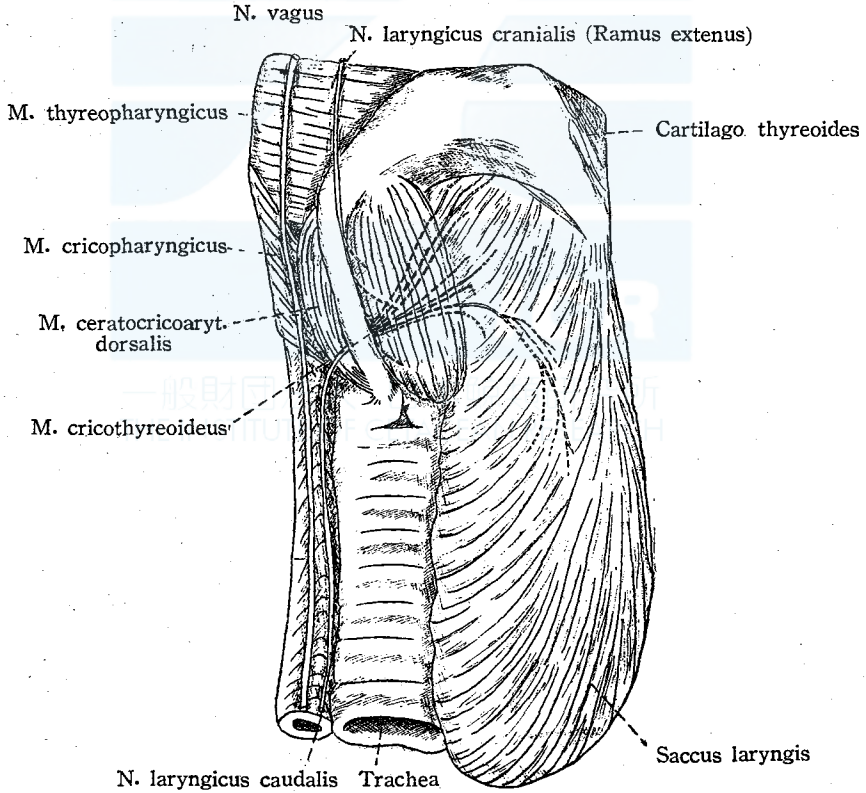


Fig. 19. Medulla oblongata of the Sei-whale (5/2)

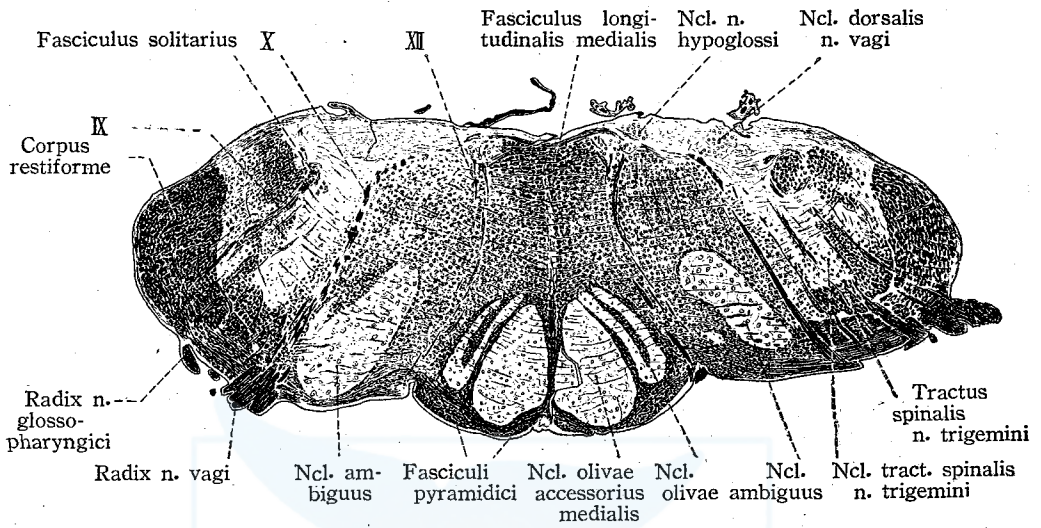


Fig. 1/b Cartilage thyreoides (Lamina dextra) (1/8)

outer surface M. thyreo-hyoideus

Fig. 1/a Cartilago thyreoides (Physeter catodon) seen from the ventro-lateral side (1/8)

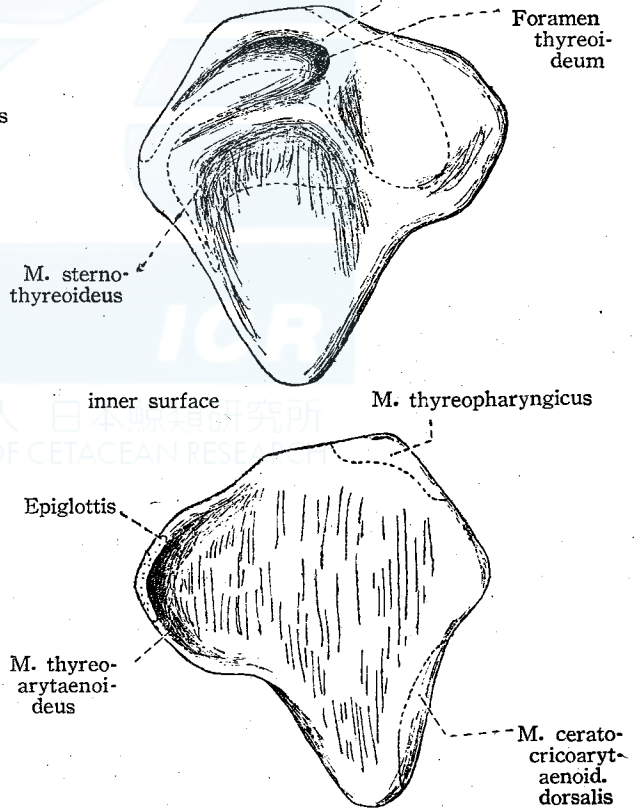
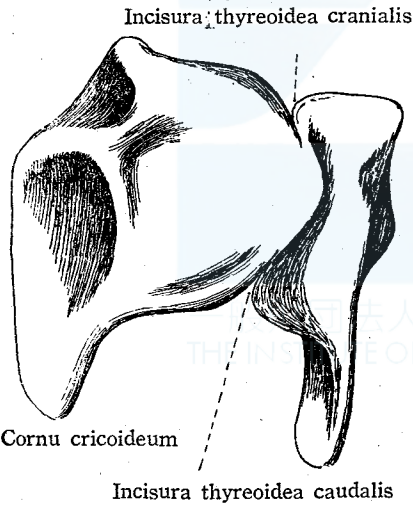
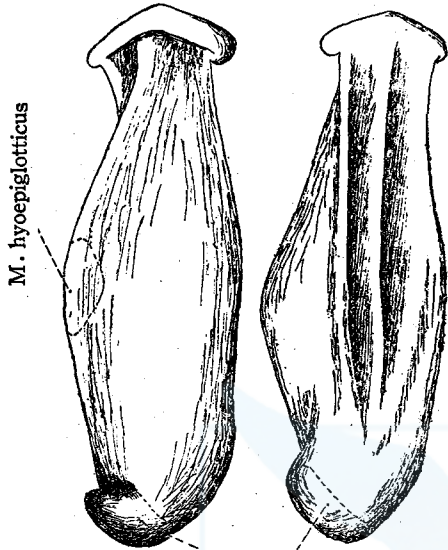


Fig. 2/a Cartilago epiglottidis (1/6)
ventro-lateral view dorso-lateral view



Syndesmosis with
the thyroid cartilage

Fig. 2/b Cartilago epiglottidis (1/6)
lateral view horizontal section

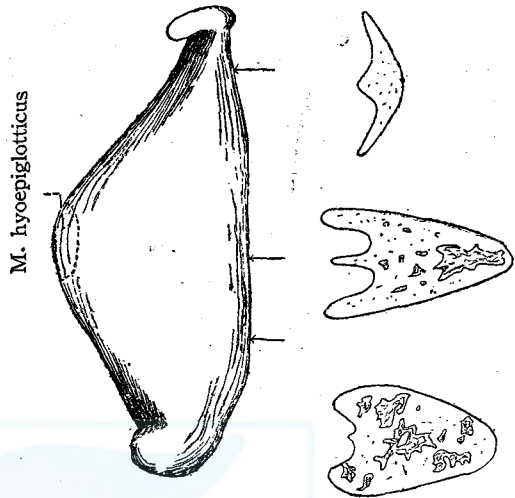


Fig. 3/ Cart. cricoides (1/6)

dorso-lateral view

ventro-lateral view

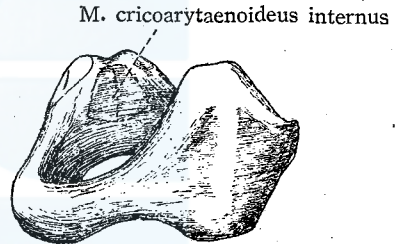
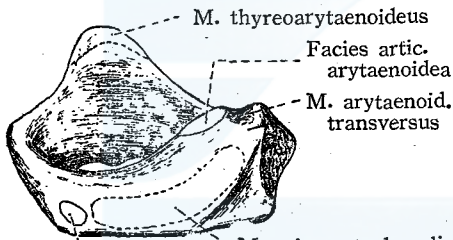


Fig. 4/a Cart. arytaenoides (1) (1/6)

ventral view

dorsal view

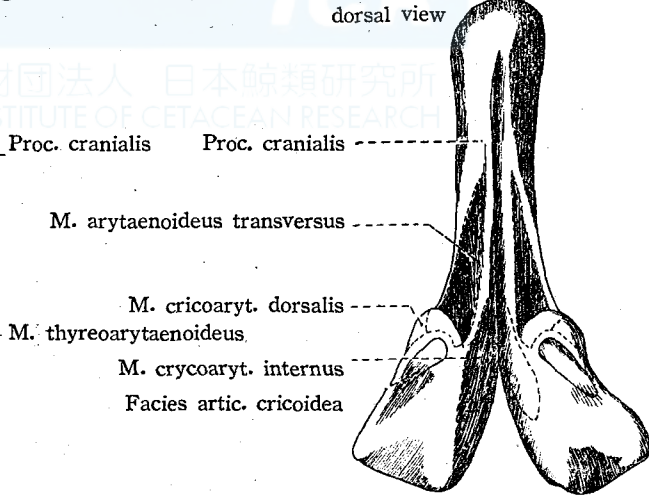
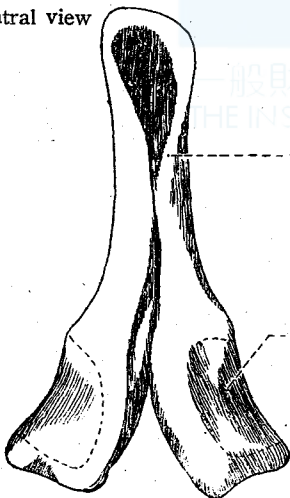


Fig. 4/b Cart. arytaenoides (sinistra) (2) (1/6)
lateral view medial view

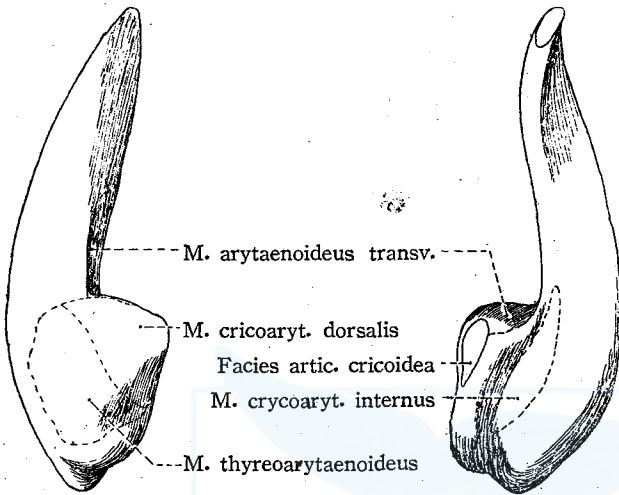


Fig. 5/a. Cartilagine tracheales (1) (1/6)
ventro-lateral view

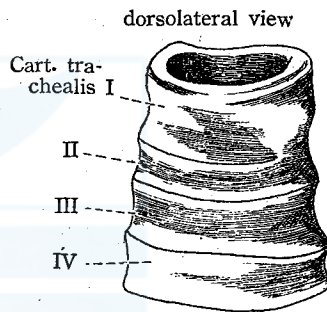
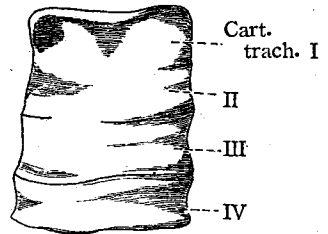


Fig. 5/b Cartilagine tracheales (2) (1/6)
median section

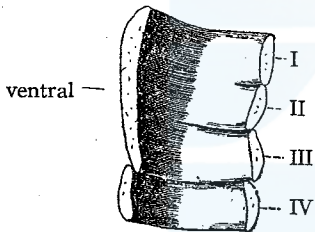


Fig. 6/ Larynx (2/9)

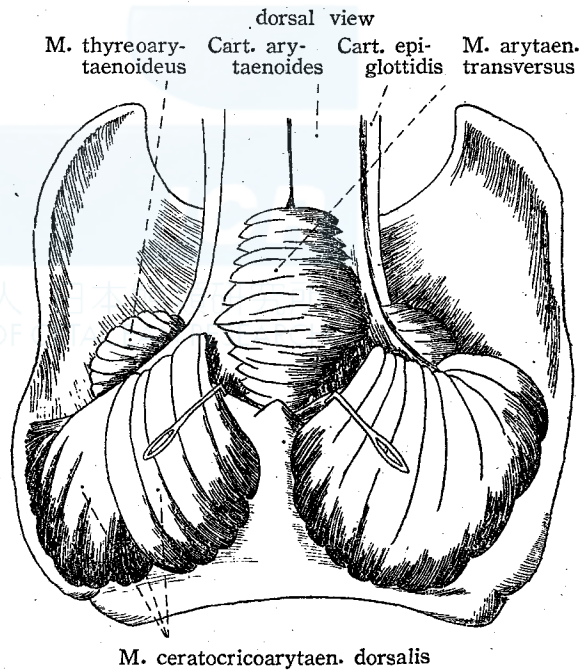


Fig. 7' Larynx (2/9)

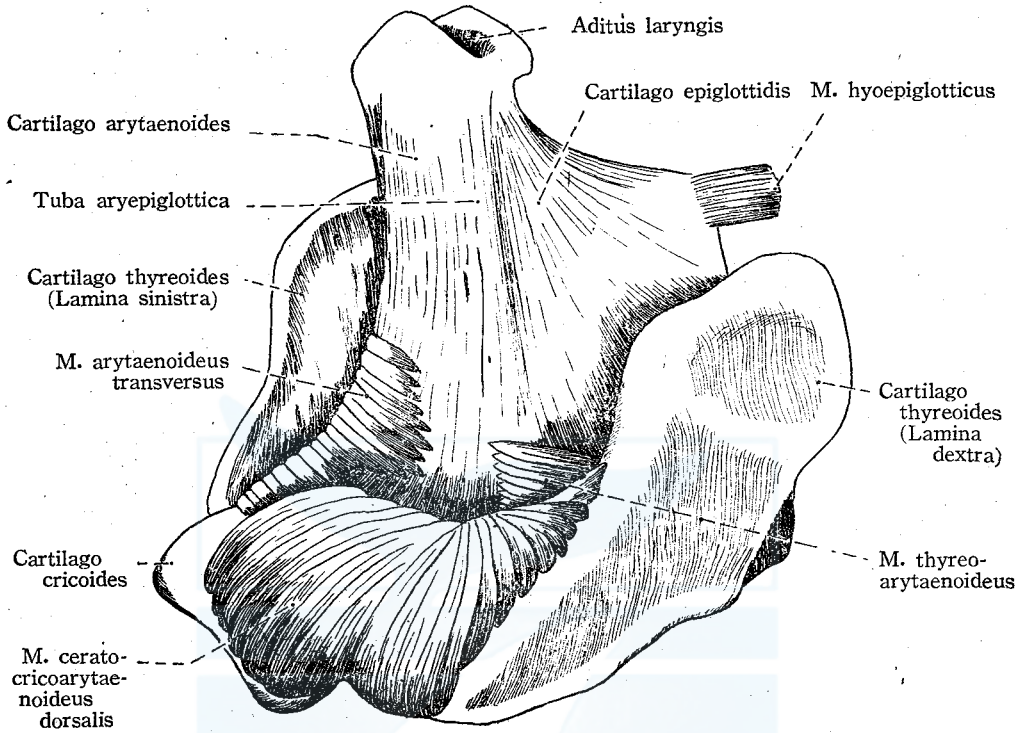


Fig. 8' Larynx (1/6)

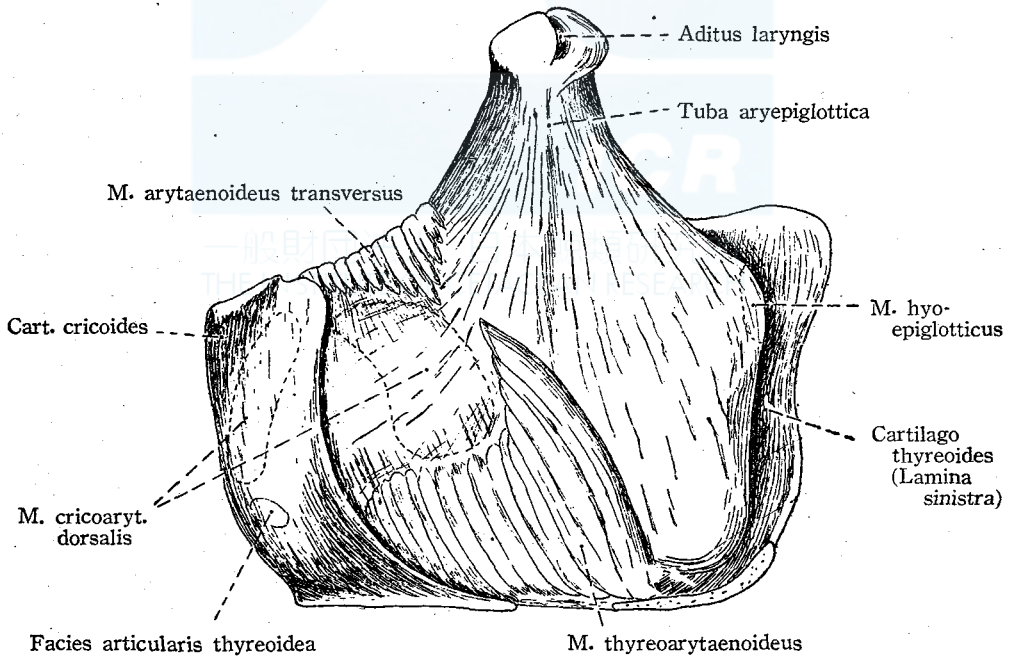


Fig. 9' *M. cricoarytaenoideus internus* (1/6)
medial view

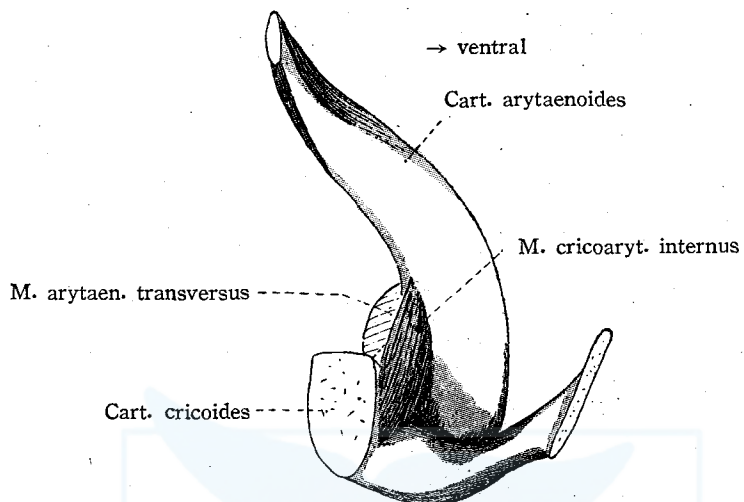


Fig. 10' Aditus laryngis (1/6)

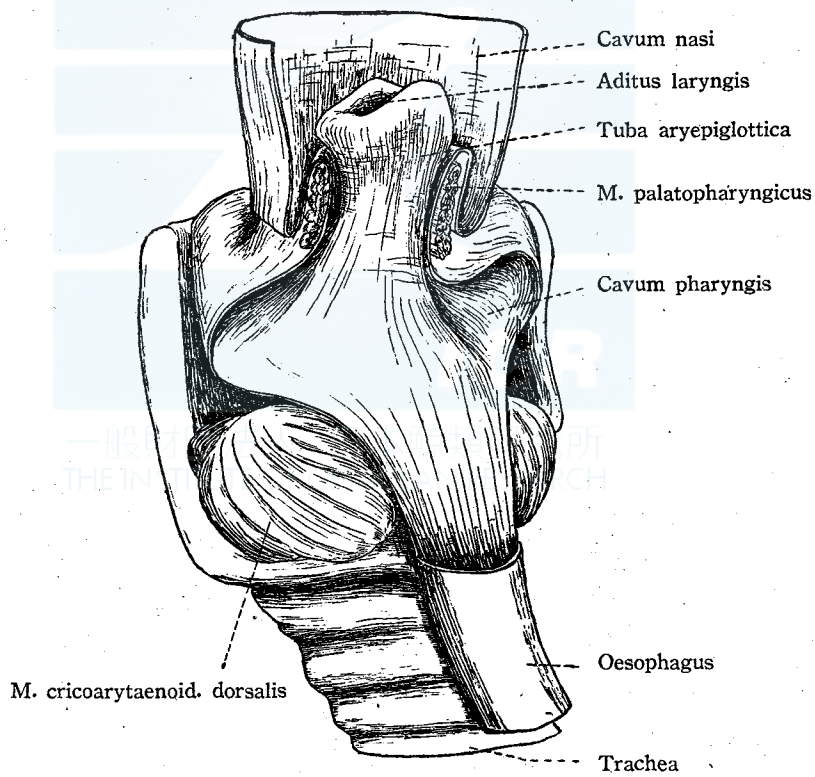


Fig. 11' Cavum laryngis (1/6)

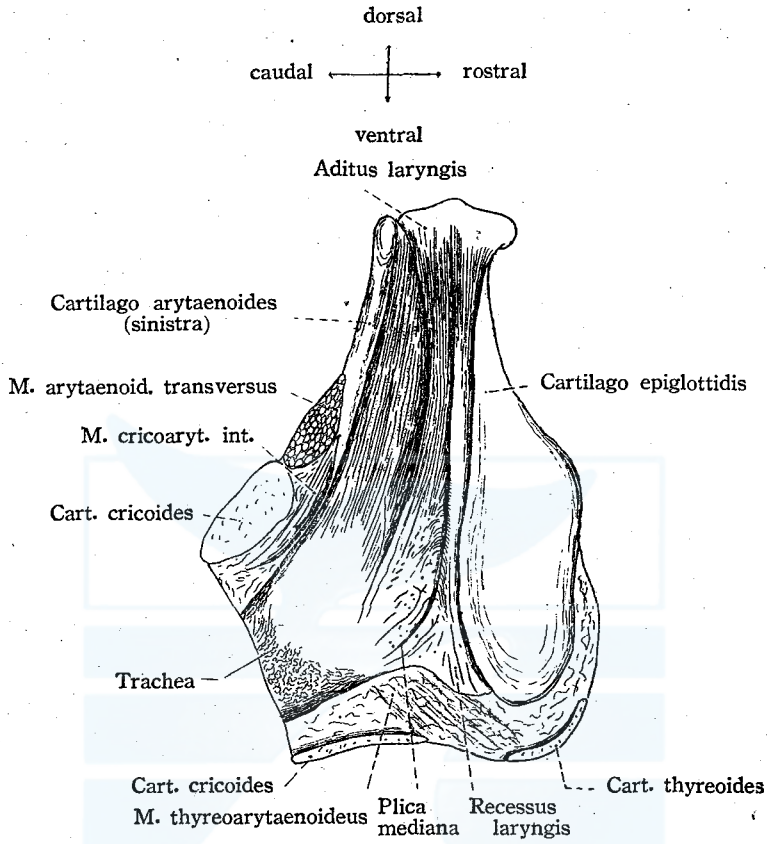


Fig. 12' Medulla oblongata of the pigmy Sprm-whale (10/3)

