

# Distribution of the Red Marrow in Bones of the Fin Whale

by

Tadahiro Ohe

Department of Anatomy (Prof. Dr. T. Ogawa),  
Medical School, University of Tokyo.

The present investigation was performed at Mombetu, Hokkaido, in the summer of 1948, when I stayed there for ten days. The object of my study was to determine the site of haematopoiesis in the body of whales, for then we had in mind a question, whether or not the blood corpuscles of the baleen whales are developed in the organs just as they are in the terrestrial mammals. Except the quite recent paper of Slijper et al (1948), which reached us after the completion of the present work, there seems to have been no detailed report upon the distribution of the red bone marrow in the baleen whales.

## Materials :

Four individuals of the Fin whale, *Balaenoptera physalus L.*, were examined. All of them were captured off the northeastern coast of Hokkaido by boats of the Taiyo Fishing Company; by the courtesy and deep understanding of the members of this company the present work could be fulfilled to the success of a certain grade.

## Methods :

Of course at the whaling station the scientific research is met with much difficulties, as speedy disposition of the whale body is the most important factor in the whaling industry and in most cases the heavy materials can only be moved by the help of winches. We can examine them not always to our hearts' content. My own experience at that occasion is as follows. The vertebral column, after most of the truncal muscles were cut off, is brought by the winch to the "bone platform"; the huge mass was separated into each segment, by cutting through the intervertebral discs. At that time I endeavoured to arrange all of the vertebral bones in the natural order, and asked one of the workers to break them lengthwise in the oro-caudal direction. Of some vertebrae the transverse and the spinous process were also cut for examination of the bone marrow. The cervical vertebrae were split longitudinally in a mass.

The dissectors used to remove the ribs altogether with intercostal muscles and pleura as a whole from the vertebral column, then to separate them into each rib and to bring them to the bone platform. At that occasion I arranged the ribs in the natural order on each side and examined their caput, cauda and the middle part, sectioning transversely. Though the ribs of the Fin whale are said to be usually fifteen pairs, there were two cases Nos. 42 and 40, in which I found only fourteen pairs. The problem, whether there were really only fourteen pairs, or one pair, probably the last, was lost at the dissection platform, is not certain. I guess the former assumption may have more truth.

To my regret, I had no chance to examine sternum and pelvis. I did not dare to find out these small bones, not to disturb too much the speedy work at the dissection platform. The chevron bones are carried to the bone platform as a long chain-like block, and I cut some of them to see the marrow.

The large skull is at first divided by the bone saw lengthwise at the middle line into right and left halves, cut then in various directions into many blocks, which are small enough to be easily dropped into the press-boiler. I examined the cut surfaces of them as much as possible. The hyoid consists of one median part (basihyal and thyroyal) and paired lateral parts (stylohyal). The stylohyal was usually not discovered, as it was carried probably to another place. I cut as a rule the hyoid bone in the median plane and further along its long axis.

The scapula was cut into two parts, a cranial and a caudal. The large projected acromion was examined especially. Bones of the pectoral limb were cut in a mass transversely into two pieces, and then in the same direction into four portions. The head of the humerus was especially observed.

I made some microscopical preparations from the red marrow and ascertained that the haematopoiesis was certainly taking place in it.

#### Results :

No. of the specimen	44	41	40	42
Body length in feet	50	52	53	67
Sex	Female	Male	Female	Female
Date of the capture	8 a. m. August 14.	5 p. m. August 12.	5 p. m. August 9.	8 a. m. August 12.

Beginning of dissection		6 p. m. August 14.	3 a. m. August 13.	6 a. m. August 10.	4 p. m. August 12.
Approximate hours elapsed between capture and dissection		10	10	11	8
Vertebral formula		7+15+14 +20=50	7+15+14 +22=58	Not especially examined.	
Atlas		The red marrow was found only in the ventral arch.			
Cervical vertebrae 2-7		Entirely filled with red marrow, but in No. 44 not so completely as in three other individuals.			
Thoracic vertebrae 1-15		Also filled with red marrow, but the white marrow <sup>(1)</sup> was present in a wedge-like form <sup>(2)</sup> in the peripheral part of the vertebral body, becoming larger in the caudal direction. <sup>(3)(4)</sup>			
Vertebrae	Lumbar and caudal vertebrae	Beginning with the 15. (in No. 42 with 14.) thoracic vertebra caudalwards the red marrow becomes irregular in shape and gradually decreases in extent, but in Nos. 41 and 40 it was present in addition along the lines of epiphysis. A red spot was found down to the 2. caudal (No. 44), to the 12. lumbar (No. 41), to the 8. lumbar (No. 40), or to the 2. caudal (No. 42).			
	Processes examined of some vertebrae (+: presence of the red marrow; -: its absence)	6. thor.+ 14. thor.- 1. lumb.-	10. thor.+ 15. thor.-	4. thor.+ <sup>(5)</sup> 7. thor.+ 10. thor.+ 14. thor.-	5. thor.+ 10. thor.+
Skull		Two small pieces of red marrow, each the size of a hen's egg, were present in the basal part, and a larger one in the roof of the brain case.	One red portion was present in the basal part and another in the frontwall of the brain case and one more in the occipital part.	Though I remember to have seen the red marrow in the skull, I can not clearly locate it.	The skull had the red marrow only in its anterior basal part.
Hyoid		Not examined.	A relatively large red portion in the thyrohyal and scattered red spots in the basihyal. Stylohyal not examined.	The red marrow was present only in the thyrohyal. The stylohyal was not observed.	The red marrow was present neither in the basi- and thyrohyal, nor in the stylohyal.
Ribs		The red marrow was present only in the caput. But only in the caput of the 10. rib of No. 41, the red marrow was mixed with the white one.			
Scapula	Glenoid	The red spot was seen.			
	Scapular plate	Three very small spots of the red marrow were found.	Here and there red marrow was present.	No red marrow	
	Acromion	No red marrow			
Bones of flipper		No red marrow			

Supplementary remarks to the table of the foregoing pages:

- (1) Man says usually "red" and "yellow" as to the bone marrow, but in the whale, especially in the vertebrae of them, the yellow marrow might be better called "white", because in the lumbar vertebrae, for instance, we get an impression, as if red ink were dropped on the snow. So I used in this paper, instead of "yellow", the term "white bone marrow." But in hyoid, scapula, and bones of the skull the yellowish colour predominates.
- (2) By cutting further, the red marrow was seen in form of an hour-glass.
- (3) In the epiphyses of the thoracic vertebrae of No. 42 the red marrow of a patch-like form is present in the center, surrounded by the white marrow; this fact was not seen in the other specimens.
- (4) In the 10. to 13. thoracic vertebra of No. 42 the dorsal wedge of the white marrow was relatively sharp and small, while the ventral white part showed more rounded contour.
- (5) The red marrow in the processes of the 4. and 7. thoracic vertebra was continued to that of the vertebral body, while that in the processes of the 10. thoracic vertebra showed no direct continuation with that of corpus.

#### Summary:

- (1) In the atlas the red marrow is present only in the ventral arch. From the 2. cervical down to the 14. thoracic vertebra the vertebral bodies are filled nearly completely with the red marrow, and as the whale advances in age, this seems to disappear in the caudo-cranial direction.

Beginning with the 15. thoracic vertebra the red marrow becomes irregular in shape and decreases suddenly in extent, but point-like red places can be found up to lumbar or caudal vertebrae.

As Slijper says, the red marrow seems to disappear earlier in the processes than in the corpus of vertebra. In the latter the white marrow appears at first in a wedge-like form in the circumferential part, and at that time the conversion of the red marrow into the white has not yet finished in the processes.

In the vertebrae of two individuals (No. 44 and No. 41), the red marrow, irregular in shape, was also present along the lines of epiphysis, but this was not the case in the other two (No. 40 and 42).

- (2) In scapula, hyoid and skull the red marrow becomes smaller with the

age. Slijper et al seem in the Blue whale not to have seen the red marrow in these bones.

- (3) In all of the costae the red marrow was present in the caput.
- (4) In bones of the flipper and in the chevrons the red marrow is completely lacking.

#### Explanation of the figures:


Except hyoid, lateral views of all of the bones are shown. The processes of vertebrae are omitted; ribs, hyoid and bones of the flipper are moved from their natural positions.

black.....red bone marrow.

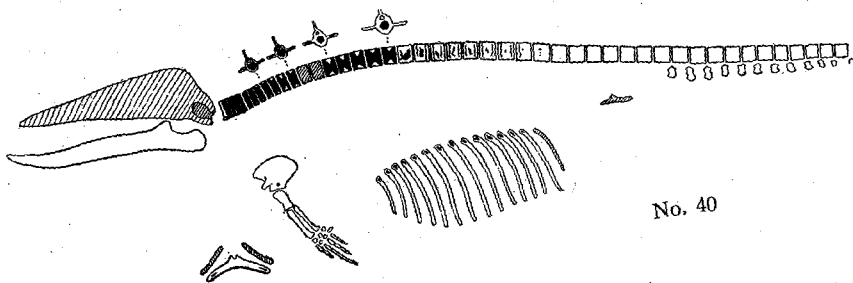
obliquely lined area.....bones not examined.

#### Literature:

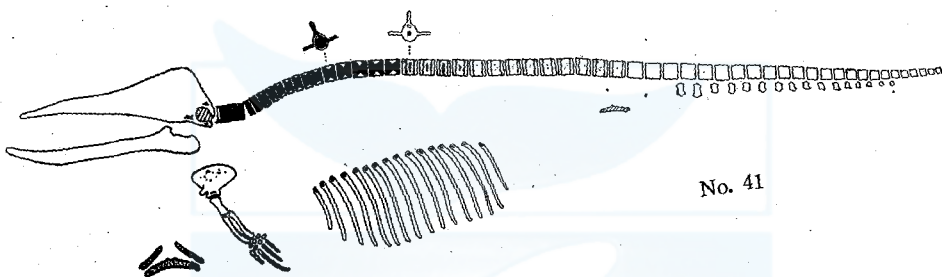
- C. F. Feltmann, E. J. Slijper and W. Vervoort: Preliminary researches on the fat-content of meat and bone of Blue and Fin whales. Koninklijke Nederlandsche Akademie van Wetenschappen. Vol. 51, No. 5 (1948) p. 604—615.



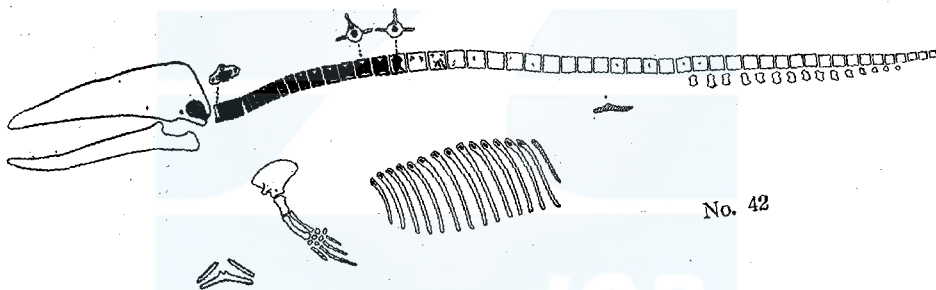
一般財団法人 日本鯨類研究所  
THE INSTITUTE OF CETACEAN RESEARCH



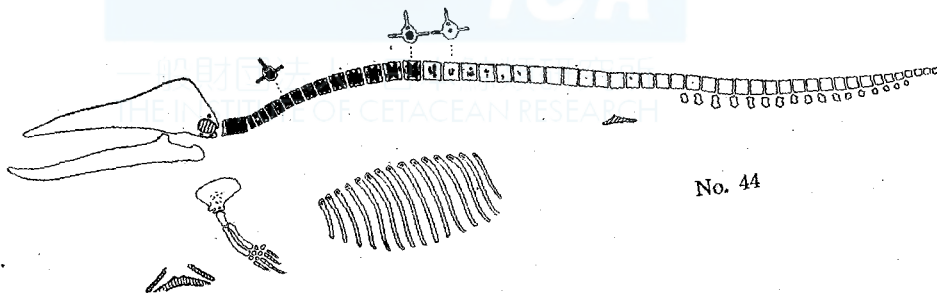
No. 40



No. 41



No. 42



No. 44